

#665

**Topic:** *AS01 Alternative medicine, homeopathy and acupuncture*

## **THE BENEFICIAL EFFECTS OF INTEGRATIVE REHABILITATION FOR B654RACHYCEPHALIC DOGS WITH HEMIVERTEBRAE**

F. Amelia<sup>1</sup>, Z. Fadhilah<sup>2</sup>, S. Siallagan<sup>3</sup>, B. Budiharjo<sup>4</sup>, A. Zahrani<sup>5</sup>

<sup>1</sup>Mody Pet's Club & RnD Clinic by My Vets, Neurology and Rehabilitation, Jakarta Selatan, Indonesia, <sup>2</sup>My Vets BSD, Integrative Medicine, Tangerang Selatan, Indonesia, <sup>3</sup>My Vets Kemang, Diagnostic Imaging, Jakarta Selatan, Indonesia, <sup>4</sup>My Vets BSD, Diagnostic Imaging, Tangerang Selatan, Indonesia, <sup>5</sup>My Vets Kemang, General Practitioner, Jakarta Selatan, Indonesia

### **Introduction:**

A hemivertebrae is a congenital disorder affecting the vertebral bodies that can lead to instability and deformity of the spinal column, which then causes the spinal cord or the nerves arising from it to become squashed and damaged.

### **Objectives:**

This report aims to describe the beneficial effects of integrating traditional and modern rehabilitation modalities on 8 brachycephalic dogs diagnosed with hemivertebrae.

### **Methods**

After the hemivertebrae was confirmed with radiology examination, all patients enrolled for rehabilitation program with various modalities such as acupuncture, hydrotherapy, proprioceptive training (PT), electrical nerve stimulation, ultrasound, and laser therapy.

### **Results**

There are 450 dogs admitted to our clinics in the January 2020-August 2021 period, of which 29 are brachycephalic breeds dominated by French bulldogs (73%). Four patients showed paraparesis with delayed and negative proprioception at the admission, one patient did not show clinical signs of hemivertebrae, and the rest with a major non-neurological health issue. The youngest patient was 5 months old, and the oldest was 6 years old. Electroacupuncture, underwater treadmill, and PT were the most chosen modalities used in all cases. Fifty percent of patients showed improvement after the second session.

### **Conclusions**

From this result, we suggest that integrative medicine, utilizing western and eastern veterinary modalities, shows a fast satisfactory result in improving ambulation in dogs with hemivertebrae.

#518

**Topic:** *AS01 Alternative medicine, homeopathy and acupuncture*

## **EVALUATION OF A NATURAL SPOT-ON FORMULATION ON AGING DOGS WITH SEBORRHEIC DISORDERS AND BEHAVIORAL UNBALANCES LINKED TO AGE**

M. Cauquil<sup>1</sup>, N. Massal<sup>2</sup>, A. Jechoux<sup>3</sup>

<sup>1</sup>LDCA, Dermoscent®, Castres, France, <sup>2</sup>Clinique de la Paix, Pau, France, <sup>3</sup>Clinique vétérinaire de la Rivière, ., Plaisance Du Touch, France

### **Introduction:**

Animal well-being including quality of life is of great concern for both owners and veterinarians. These concerns might become difficult to address for aging animals whose expectancy increases. Other than severe health issues, aging pets develop easily cutaneous and behavioural unbalances. Phytotherapy and aromatherapy are of high interest since numerous owners appreciate natural solutions.

### **Objectives:**

To evaluate the effect of a spot-on (SILVER Spot®, Dermoscent®, LDCA) based on plant-extracted essential fatty acids, a specific essential oil synergy and other natural ingredients, indicated for aging animals.

### **Methods**

Eight aged dogs were enrolled in this open study. The spot-on was applied once a week during 8 weeks. Behavioural veterinarians evaluated skin and behaviour parameters, by scoring methods at D0, D21, D42 and D56. Statistical analysis was performed with ANOVA.

### **Results**

The mean age was 14.25 yo. Both odour and coat shine were significantly improved ( $p < 0.01$ ) at D56 by respectively 78% and 121%. All dogs showed either greasy or dry skin at D0, and the balance was restored at D56 ( $p = 0.073$ ). Sleep quality was improved by 123% ( $p < 0.001$ ) to reach an average score of 3.625/4. Six dogs were more prone to play or go outdoors after treatment ( $p < 0.05$ ) showing significant improvement, whereas the 2 others being already at the maximal score at D0. Dogs were more receptive to respond to owners' requests at D56 (+263%,  $p < 0.01$ ).

### **Conclusions**

Applying SILVER spot® for 8 weeks in aged dogs has been beneficial for kerato-seborrheic disorders and behavioral unbalances. A future controlled study would be useful.

**Topic:** *AS01 Alternative medicine, homeopathy and acupuncture*

**IMPACT OF FEEDING TREATS CONTAINING CANNABIDIOL (CBD) ON CANINE IMMUNE RESPONSE TO IMMUNIZATION WITH A NOVEL ANTIGEN**

E. Morris<sup>1</sup>, S. Kitts-Morgan<sup>2</sup>, D. Spangler<sup>2</sup>, K. Mcleod<sup>1</sup>, D. Harmon<sup>1</sup>

<sup>1</sup>University of Kentucky, Animal And Food Sciences, Lexington, United States of America, <sup>2</sup>Lincoln Memorial University, College Of Veterinary Medicine, Harrogate, United States of America

**Introduction:**

One concern regarding CBD is its potential to negatively impact the immune system.

**Objectives:**

The objective of this study was to evaluate the effect of CBD on canine immune response to immunization with keyhole limpet hemocyanin (KLH).

**Methods:**

Thirty-two dogs (22.4±6.3 kg BW) were utilized in a completely randomized design. Treatments consisted of 5 mg CBD/kg BW/d vs control. After 7-d acclimation, dogs were immunized with 10 mg/dog of KLH via intramuscular injection, which was repeated in 14 d. Blood samples were collected at baseline and weekly for 28 d after initial KLH immunization for analysis of hematology, serum chemistry, and immunoglobulins. Data were analyzed using the MIXED procedure in SAS including fixed effects of treatment, day, and accompanying interaction.

**Results:**

Primary and secondary KLH immunization produced robust immune responses. Total and KLH-specific IgG and IgM were similar between treatments ( $P>0.05$ ), though total IgM peaked earlier in control than CBD. Most hematological and serum chemistry variables remained within normal reference ranges for dogs across both treatments throughout the study. Alkaline phosphatase, while within normal reference range and similar between treatments at baseline and on d 7 ( $P=0.994$  and  $0.183$ , respectively), was elevated for CBD on d 14, 21, and 28 ( $P=0.006$ ,  $0.027$ , and  $0.014$ , respectively).

**Conclusions:**

Despite the shift in IgM peak timing, CBD did not appear to exhibit immunosuppressive effects when supplemented at 5 mg/kg BW/d. However, this work highlights the potential for CBD to alter liver function and the need for further safety evaluations utilizing longer-term studies and multiple doses.

**P002 / #558**

**Topic:** *AS02 Anesthesia*

**COMPARISON OF THE EFFECTS OF BUTORPHANOL OR BUPRENORPHINE COMBINED WITH DEXMEDETOMIDINE AND KETAMINE ON THE RESPIRATORY FUNCTION OF RABBITS.**

V. Papageorgiou, T. Anagnostou, I. Savvas, A. Komnenou, D. Anastasiadou, G. Kazakos  
Aristotle University of Thessaloniki, Veterinary Science, Thessaloniki, Greece

**Introduction:**

The combination of  $\alpha_2$  agonists and ketamine is widely used in rabbits and is considered effective. However, the addition of an opioid for pain control would be beneficial in many cases.

**Objectives:**

To determine the respiratory effects, as derived from arterial blood gas analysis, of the addition of either butorphanol or buprenorphine to the combination of dexmedetomidine and ketamine in rabbits.

**Methods:**

Forty- two New Zealand White, healthy rabbits sedated for intraocular injection were used in this study and were randomly allocated to two groups. Group A animals (n= 21) received an intramuscular injection of dexmedetomidine ( $250 \mu\text{g kg}^{-1}$ ), ketamine ( $15 \text{ mg kg}^{-1}$ ) and butorphanol ( $0.1 \text{ mg kg}^{-1}$ ), while Group B animals (n= 21) received dexmedetomidine ( $250 \mu\text{g kg}^{-1}$ ), ketamine ( $15 \text{ mg kg}^{-1}$ ) and buprenorphine ( $0.03 \text{ mg kg}^{-1}$ ). Arterial blood samples were obtained at three time points: before anesthesia (T0), after the loss of the righting reflex (T1) and when the righting reflex recovered (T2). Respiratory frequency,  $\text{PaCO}_2$  and  $\text{PaO}_2$ , arterial Ph and blood bicarbonate were evaluated at 21% fraction of inspired oxygen. When hypoxia was detected, supplemental oxygen was administered.

**Results:**

Statistically non- significant differences were observed in the evaluated parameters between the two groups. However, a significant decrease of  $\text{PaO}_2$  at T1 and T2 was observed in both groups.

**Conclusions:**

In healthy rabbits, arterial blood gas analysis and respiratory frequency results do not differ significantly between the anesthetic protocols that include dexmedetomidine, ketamine and butorphanol or buprenorphine. However, oxygen supplementation is considered essential when these anesthetic protocols are used.

**P003 / #561**

**Topic:** *AS02 Anesthesia*

## **A CASE OF DELAYED RECOVERY FROM ANAESTHESIA IN A DOG DUE ADDISONIAN CRISIS: A CASE REPORT**

V. Papageorgiou, T. Anagnostou, I. Savvas, G. Kazakos  
Aristotle University of Thessaloniki, Veterinary Science, Thessaloniki, Greece

### **Introduction:**

Delayed recovery from anaesthesia is commonly encountered in dogs however, it may be caused by rare conditions.

### **Objectives:**

To present a case of delayed recovery in a dog after surgery due to presumed atypical Addisonian crisis.

### **Methods:**

A 4-year-old Pincher was anaesthetized to undergo dental surgery in a first opinion veterinary clinic. The recovery from anaesthesia was prolonged and the dog was referred to our ICU. Physical examination revealed mild bradycardia (80 bpm), decreased arterial blood pressure (MAP 70 mmHg) as well as decreased blood glucose (50 mg/dl). Arterial blood gas analysis, diagnostic imaging, haematology and biochemistry were unremarkable. Crystalloids were administered as a constant rate infusion ( $10 \text{ ml kg}^{-1} \text{ h}^{-1}$ ) in order to restore arterial blood pressure. In addition, glucose 35% ( $1 \text{ ml kg}^{-1}$ ) was administered as a bolus. After two hours of aggressive fluid therapy and glucose monitoring the dog showed mild improvement of heart rate (100 bpm) but blood pressure remained mildly decreased (MAP 80 mmHg). ACTH stimulation test revealed hypoadrenocorticism, despite normal sodium and potassium concentrations due to presumed glucocorticoid deficiency. Thus, a bolus of dexamethasone ( $0.25 \text{ mg kg}^{-1}$ ) was administered intravenously. Approximately one hour after dexamethasone administration and fluid therapy, the cardiovascular parameters were restored, and clinical condition of the dog was stabilized.

### **Results:**

A diagnosis post-anaesthetic atypical Addisonian crisis due to presumed glucocorticoid deficiency was made. The next day, the dog remained stable and was discharged from ICU.

### **Conclusions:**

A rare cause of prolonged recovery from anaesthesia may be related to the cardiovascular effects from Addisonian crisis.

**P004 / #595**

**Topic:** *AS02 Anesthesia*

**VERIFICATION OF THE NECESSITY OF MAINTENANCE ANAESTHESIA WITH ISOFLURANE AFTER INDUCTION WITH TILETAMINE-ZOLAZEPAM IN DOGS USING THE DIXON'S UP-AND-DOWN METHOD.**

S. Lachowska<sup>1,2</sup>, A. Antończyk<sup>1,2</sup>, J. Tunikowska<sup>1</sup>, P. Kucharski<sup>1,2</sup>, B. Liszka<sup>1</sup>, P. Prządka<sup>1</sup>, Z. Kielbowicz<sup>1</sup>

<sup>1</sup>Wrocław University of Environmental and Life Science, Faculty Of Veterinary Medicine; Department And Clinic Of Surgery, Wrocław, Poland, <sup>2</sup>Wrocław University of Environmental and Life Sciences, Faculty Of Veterinary Medicine; Department And Clinic Of Surgery, Wrocław, Poland

**Introduction:**

Isoflurane is one of the most commonly used anaesthetic gases in veterinary medicine. Due to its numerous side effects, intravenous anaesthesia is more often used. The combination of tiletamine with zolazepam has proved to be a safe and pharmacologically beneficial combination. The main advantages of this two drugs are analgesic effect, fast induction time, effective myorelaxation and smooth recovery.

**Objectives:**

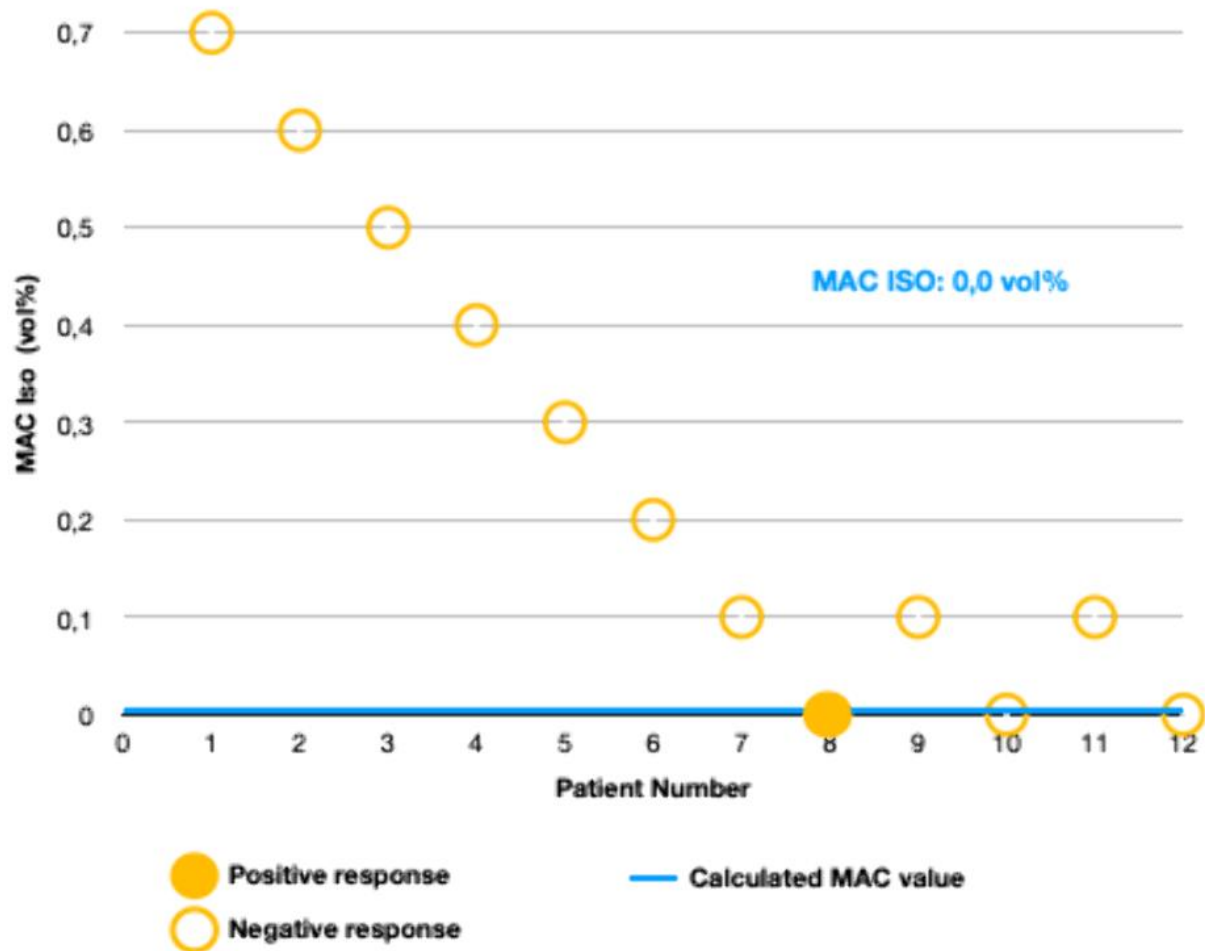
The objectives of this work was the verification of the necessity of maintenance anaesthesia with isoflurane in pain stimulation using the induction of tiletamine-zolazepam by the up-and-down method.

**Methods:**

12 dogs were selected to the group with the inclusion criteria: ASA I or II. Each dog received premedication intramuscularly with medetomidine-butorfanol (10 µg/kg, 0,1 mg/kg respectively). After 15 minutes of premedication, preoxygenation was started and it lasted for 5 minutes. Anaesthesia was induced with tiletamine-zolazepam at the dose of 5 mg/kg. Then the dogs were intubated and anaesthesia was maintained with isoflurane. Initially, MAC was set to 0.7 vol.%. After 15 minutes equilibration, MAC was determined using Dixon's up-and-down method. Painful stimulation including compressions of paw pad, phalange, groin area, and clamping Backhaus on skin. Hemodynamic and ventilation parameters were measured and noted in 2 minutes intervals.

**Results:**

Results are shown in chart:



### Conclusions:

The results show that isoflurane is not necessary to maintain anaesthesia after tiletamine-zolazepam induction. This is clinically important because the side effects resulting from using isoflurane are eliminated.

**P005 / #596**

**Topic:** *AS02 Anesthesia*

**RECOVERY PERIOD AFTER PARTIAL INTRAVENOUS ANAESTHESIA USING  
TILETAMINE-ZOLAZEPAM COMBINATION AS A CONTINUOUS RATE INFUSION  
EVALUATED WITH SEDATION ASSESMENT AND COMPOSITE MEASURE PAIN SCALE.**

P. Kucharski, A. Antończyk, P. Prządka, B. Liszka, S. Lachowska, Z. Kielbowicz  
Wrocław University of Environmental and Life Sciences, Faculty Of Veterinary Medicine;  
Department And Clinic Of Surgery, Wrocław, Poland

**Introduction:**

Tiletamine is a dissociative drug, N-methyl-D-aspartate (NMDA) receptor antagonist. Tiletamine is always combined with zolazepam in equal parts (1:1). Because of the fact that zolazepam is eliminated quicker than tiletamine in dogs, we could observe dissociative symptoms, which worsens the recovery period.

**Objectives:**

To assess recovery period after partial intravenous anaesthesia (PIVA) protocol with use of tiletamine-zolazepam (TZ) combination as a CRI and isoflurane in oxygen in low doses.

**Methods:**

15 female dogs classified for laparoscopic ovariohysterectomy were used in this case study. Premedication with dexmedetomidine at a dose of 500 µg/m<sup>2</sup> and induction of general anaesthesia with 1mg/kg of tiletamine-zolazepam was obtained. Maintenance was provided with CRI of TZ at a dose of 1mg/kg/h and isoflurane (0.2 MAC) in oxygen. During recovery period composite measure pain scale–short form (CMPS-SF) and Sedation Assessment were obtained in 4 timepoints (P0, P0,5, P1, P2).

**Results:**

At timepoint P0 and P0,5 all dogs showed high level of sedation and no pain symptoms. At timepoint P1 two dogs showed a high level of sedation while the rest of the patients showed low level or no sedation symptoms. One patient required emergency analgesia after 1 hour of recovery period. Mean time of retaining sternal recumbency was 82.66 ± 26.67 (mean ± SD) minutes. Time to achieve standing position was 103.4 ± 25.33 minutes. Dogs did not show any dissociation symptoms during the recovery period except for one patient.

**Conclusions:**

The recovery period after PIVA protocol with use of TZ as a CRI was good in 14 in 15 dogs.



**P006 / #615**

**Topic:** *AS02 Anesthesia*

## **COMPARATIVE STUDY FOR NEONATAL OUTCOME AND UMBILICAL CORD BLOOD GAS PARAMETERS IN BALANCED AND INHALANT ANESTHESIA FOR ELECTIVE CESAREAN SECTION IN DOGS**

A. Antończyk<sup>1</sup>, Z. Kielbowicz<sup>1</sup>, W. Niżański<sup>2</sup>, M. Ochota<sup>2</sup>

<sup>1</sup>Wrocław University of Environmental and Life Sciences, Faculty Of Veterinary Medicine; Department And Clinic Of Surgery, Wrocław, Poland, <sup>2</sup>Wrocław University of Environmental and Life Sciences, Department Of Reproduction And Clinic Of Farm Animals, Wrocław, Poland

### **Introduction:**

Umbilical cord blood gas analysis (UCBG) in human medicine is an important indicator of neonatal oxygenation and acid- base status and its results, combined with Apgar scores, may reveal the effect of anaesthesia protocol on fetal outcomes.

### **Objectives:**

This study aimed to compare the influence of balanced and inhalant anesthesia on UCBG parameters and vitality.

### **Methods:**

The bitches undergoing elective CS were enrolled into this study. Females were randomly assigned into: Gr I (Isoflurane, n=16) and Gr IE (Isoflurane plus Epidural, n=15). Anesthesia was induced with propofol, and maintained with isoflurane in oxygen, in IE group epidural anesthesia was also done (Lidocaine). Mixed umbilical blood was collected by double clamping of the cord. The modified Apgar scoring system (AS) was used to score neonatal health at 0, 5 and 20 min after birth.

### **Results:**

The IE group required a lower isoflurane concentration. All investigated UCBG parameters were not statistically different between groups. All pups had mild acidosis with moderately elevated pCO<sub>2</sub>, HCO<sub>3</sub><sup>-</sup> on the lower border, lowered BE and mildly elevated level of lactates. The initial Apgar score results were similar in I and IE groups. However, the subsequent measurements revealed differences between both groups. Puppies from the IE group received better AS scores at 5 and 20 min.

### **Conclusions:**

Epidural anesthesia reduced the requirement for isoflurane and did not affect the neonatal umbilical blood gas results. Moreover, newborns from IE group were scored higher in AS at 5 and 20 min, indicating their better vitality and quicker improvement post-surgery.

**P007 / #618**

**Topic:** *AS02 Anesthesia*

## **DESCRIPTION AND VALIDATION OF A NEW DESCRIPTIVE AND MULTIPARAMETRIC NUMERIC RATING SCALE TO ASSESS SEDATION IN CATS**

A.-A. Rutherford, A. Sanchez, G. Monteith, T. Tisotti, R. Aguilera, A. Valverde  
Ontario Veterinary College, Clinical Studies, Guelph, Canada

### **Introduction:**

The use of sedatives in cats is common practice. They facilitate diagnostic procedures, anesthetic induction, and routine examinations. Currently, there is no known validated feline specific sedation score to assess the effectivity of sedation protocols.

### **Objectives:**

To design and assess the validity and reliability of a newly developed feline multiparametric sedation scale (FMSS) and determine concordance between raters with different levels of expertise.

### **Methods:**

Eighty-seven cats were assessed before and after drug administration. Each assessment was completed by three blinded observers with different levels of expertise. A Visual Analogue Score (VAS) and Simple Qualitative Score (SQS) were included for comparison. Data was analyzed for concordance, correlation (Lin's and Spearman's tests), and inter-observer agreement (weighted kappa) using SAS statistical software. A Wilcoxon Sign Rank test was used to assess differences between pre- and post-scores among all observers.

### **Results:**

Results revealed excellent inter-observer agreement amongst all experience groups with weighted kappa scores of 0.84, 0.82 and 0.84 ( $P < 0.0001$  for all). A high degree of association was detected between FMSS and VAS ( $r = 0.90$ ,  $p < 0.0001$ ) and SQS ( $r = 0.89$ ,  $p < 0.0001$ ). The FMSS scale was able to detect significant differences between pre- and post-sedation values ( $P = 0.001$ ).

### **Conclusions:**

The FMSS appears to be a useful tool to assess sedation in cats with great internal consistency and sensitivity, regardless of the experience level of its user. Our results suggest that this score may be used when an objective numerical sedation quantification is required in both a clinical and research setting.

**P008 / #647**

**Topic:** *AS02 Anesthesia*

## **DIGITALIZATION AND MECHANIZATION OF HUMAN TACTILE SENSE DURING EPIDURAL ANESTHESIA**

S. Rhee<sup>1</sup>, W.-G. Son<sup>1</sup>, D.S. Jun<sup>2</sup>, Y. Chang<sup>2</sup>, S.G. Lee<sup>2</sup>, D. Shin<sup>1</sup>, J. Kim<sup>1</sup>, T. Sung<sup>2</sup>, S.J. Yoon<sup>2</sup>, I. Lee<sup>1</sup>

<sup>1</sup>College of Veterinary Medicine, Seoul National University, Department Of Veterinary Clinical Sciences, Seoul, Korea, Republic of, <sup>2</sup>Gacheon University, School Of Medicine, Incheon, Korea, Republic of

### **Introduction:**

Human's tactile sense refers to the varying pressure obtained by the law of action and reaction rather than static pressure. VETPIA™, a digitalized epidural anesthesia assistant device, assists the needle to advance mechanically by motor-powered electric force and to stop automatically at the epidural space.

### **Objectives:**

As for a small animal, epidural anesthesia solely by loss of resistance(LOR) technique is difficult. Therefore, a comparative study between LOR+hanging drop and VETPIA™ was performed.

### **Methods:**

Fourteen healthy Beagle dogs (7.5±2.4 kg) were divided into two groups for applying two methods. Each dog was anesthetized using medetomidine (10 µg/kg), alfaxalone (2 mg/kg) and isoflurane, and positioned in sternal recumbency with pelvic limbs extended cranially. Three anesthesiologists performed lumbosacral epidural approach at intervals of 2 weeks. A detection of epidural space was determined by the existing techniques and VETPIA™. Neurological examinations and pre- and post-anesthesia MRI were scanned for checking the complications.

### **Results:**

For three anesthesiologists, a success rate of epidural insertion was 100%, 100% and 85.7% in both methods. No complications related to epidural approach were observed in behaviors and MRI examinations.

### **Conclusions:**

Despite a limited number of trials, VETPIA™ was feasible to substitute for human tactile sense in epidural anesthesia. The device could facilitate clinical application of epidural anesthesia by a general practitioner who does not have much experience. **ACKNOWLEDGEMENTS:** This research was supported by Basic Science Research Promotion program through NRF of Korea funded by Ministry of Education, Science and Technology (2020R1I1A1A01069247),

RIMSCIENCE Co. Ltd., BK21 PLUS program and Research Institute of Veterinary Science,  
Seoul National University.

**P009 / #587**

**Topic:** *AS03 Animal Welfare*

## **OUTCOMES ASSOCIATED WITH A COMMUNITY CAT PROGRAM BASED ON HIGH-INTENSITY STERILIZATION OF OWNED, SEMI-OWNED AND UNOWNED CATS IN TARGET AREAS**

J. Rand<sup>1,2</sup>, J. Cotterell<sup>3</sup>

<sup>1</sup>Australian Pet Welfare Foundation, N/a, Fig Tree Pocket, Australia, <sup>2</sup>The University of Queensland, School Of Veterinary Science, Gatton, Australia, <sup>3</sup>City of Banyule, Animal Management, Banyule, Australia

### **Introduction:**

Cat outcomes for cats in shelters and municipal facilities are considerably worse than for dogs in most countries where straying cats or cats causing nuisances are impounded. Return to owner rates are usually much lower than for dogs, because few impounded cats are identified. This is compounded by many cats being fed by semi-owners who do not perceive the cat is their property.

### **Objectives:**

To assess the outcome of a contemporary community cat program based on high intensity free-sterilization programs targeted to suburbs with high cat intake and euthanasia or cat-related complaints.

### **Methods:**

Data were collected for intake and euthanasia before and after implementation of a community cat program focused on providing free sterilization for owned, semi-owned and unowned cats, including colony cats, in targeted areas. Where possible, semi-owners were converted to owners. Survey data were also collected from people enrolling cats in the program.

### **Results:**

A significant reduction in intake and euthanasia occurred within the first 12 months in the targeted areas. Of cats sterilized, 85% were considered owned, 15% semi-owned, of which all became owned by the carer. One in 20 semi-owners were feeding a colony, all of which were on private land, and could be managed by desexing in a way that technically was not illegal, although TNR is illegal in the target areas.

### **Conclusions:**

Community cat programs based on desexing owned and semi-owned cats are more effective in reducing intake, euthanasia and cat-related complaints than current methods of cat management based on trap-adopt or kill.

**P010 / #589**

**Topic:** *AS03 Animal Welfare*

## **A RISE IN POPULARITY OF BRACHYCEPHALIC CATS IN ISRAEL LEADS TO WELFARE CONCERNS**

Y. Arbel<sup>1</sup>, D. Ben-Dov<sup>2</sup>, L. Plitman<sup>2</sup>, Z. Avni<sup>2</sup>

<sup>1</sup>Ministry of Agriculture and Rural Development, Veterinary Services And Animal Health, Ben Gurion Airport, Israel, <sup>2</sup>Ministry of Agriculture and Rural Development, Veterinary Services And Animal Health, Beit Dagan, Israel

### **Introduction:**

Selective breeding of the domestic cat has been done primarily for aesthetic traits, with some favoring brachycephalic features. These breeds often suffer from health and welfare issues as a result of their conformation, which is becoming increasingly extreme. To date, little is known about the demand for purebred cats, including brachycephalic breeds, in Israel.

### **Objectives:**

To evaluate the trends in popularity of brachycephalic breeds, using data on cat imports into Israel alongside sale ads.

### **Methods:**

Data on cat importations into Israel was extracted from January 2012 to July 2021. Sale ads for cats were reviewed in July 2021 from two pet-selling websites. The cats were classified as either mixed/unknown breeds (MIX), pedigree breeds (PB), or brachycephalic (BRACHY).

### **Results:**

From 2012 to 2020 the number of imported cats increased 4-fold, and PB by 4.5 (54 to 212 and 30 to 136, respectively). BRACHY increased 23-fold (2 to 46) during the same period. In the first seven months of 2021 82.2% of cats imported into Israel were PB, of these 41.5% were BRACHY. BRACHY sale ads constituted 49.5% of the ads for selling cats in one of the websites, and 67.4% in the other.

### **Conclusions:**

The number of imported cats increased in recent years with BRACHY constitute more than one-third of imported cats and close to two-thirds of cats offered for sale. This increase in popularity raises concern for brachycephalic cats' welfare and begs further investigation regarding Israeli owners' awareness of the health and welfare problems of these breeds, as well as consideration for their welfare during international transport.

## METABOLIC CHANGES IN THE SALIVA OF DOGS WITH OBESITY

A. Muñoz-Prieto<sup>1</sup>, I. Rubić<sup>1</sup>, A. Horvatić<sup>2</sup>, A. Ortín-Bustillo<sup>3</sup>, L. Franco Martínez<sup>3</sup>, R. Baric-Rafaj<sup>4</sup>, J. Cerón<sup>3</sup>, A. Tvarijonaviciute<sup>3</sup>, V. Mrljak<sup>1</sup>

<sup>1</sup>Faculty of Veterinary Medicine, University of Zagreb, Clinic For Internal Diseases, Zagreb, Croatia, <sup>2</sup>Faculty of Food Technology and Biotechnology, University of Zagreb, Department Of Chemistry And Biochemistry, Zagreb, Croatia, <sup>3</sup>Interdisciplinary Laboratory of Clinical Analysis, Interlab-UMU, Regional Campus of International Excellence 'Campus Mare Nostrum', University of Murcia, Animal Medicine And Surgery, Murcia, Spain, <sup>4</sup>Faculty of Veterinary Medicine, University of Zagreb, Department Of Chemistry And Biochemistry, Zagreb, Croatia

### Introduction:

Obesity is defined as an excessive bodyweight that causes several disorders and induces important metabolic disturbances in dogs [1]. The study of metabolic changes can be performed by metabolomics analysis, a high-throughput technique that allows the quantification of a large panel of selected metabolites [2]. The application of this technique into canine saliva samples might help to understand the pathological processes occurring in this disease using a non-invasive diagnostic method [3].

### Objectives:

Therefore, the aim of this study was to investigate the variations of the salivary metabolome in dogs with obesity.

### Methods:

Saliva samples from ten male Beagle dogs were compared with nine healthy dogs using a targeted metabolomic approach.

### Results:

Metabolomics quantified a total of 234 metabolites. Of these, after a multivariate analysis significant changes were found in two amino acids: citrulline and lysine, that can be related to gain weight and the development of type 2 diabetes mellitus (T2DM) in dogs associated to obesity. Also, the disturbance of lipids was revealed by significant changes metabolites from the glycerides group (diglycerides and triglycerides) that are also linked to predisposition to T2DM.

### Conclusions:

Obesity induces changes in the metabolism of dogs that can be detected in saliva using metabolomic techniques. The variation of metabolites from the group of amino acids and glycerides could be related to the possible predisposition to T2DM associate to obesity. Therefore saliva can be a potential source of biomarkers for obesity and its complications.

**P012 / #566**

**Topic:** *AS06 Critical care and emergency medicine*

## **THE USE OF SMALL-BORE WIRE-GUIDED CATHETERS FOR THE MANAGEMENT OF PERITONEAL EFFUSION IN CATS AND DOGS**

J. Crosby, S. Cook, K. Humm

Royal Veterinary College, Queen Mother Hospital For Animals, HATFIELD, United Kingdom

### **Introduction:**

The use of percutaneously placed peritoneal catheters is described in people with uroabdomen, malignant ascites, post-surgical peritonitis, post-laparotomy peritoneal gas and intra-abdominal or pelvic abscesses. In veterinary medicine small-bore wire-guided catheters are predominantly used for management of pleural space and pericardial disease; their use in the management of peritoneal effusion has not been described in the literature.

### **Objectives:**

To describe the use of small-bore wire-guided catheters in the management of peritoneal effusion in cats and dogs and to detail any adverse events.

### **Methods:**

Retrospective study including 45 client-owned animals presenting to a university teaching hospital that had peritoneal catheters placed for management of peritoneal effusion between July 2010 and June 2021

### **Results:**

Forty-five cases were included (25 dogs and 20 cats). Twenty-eight had the catheter placed to stabilise animals with uroabdomen, 7 of which recovered without surgical management, 11 had haemoabdomen and the catheters were used for a total of 13 autotransfusions, 3 had peritonitis, and 3 had ascites secondary to cardiac disease. Thirty-three cases (17 dogs and 16 cats) received sedation (n=24), local anaesthesia alone (n=3), or general anaesthesia (n=6) to facilitate catheter placement. Median length of catheter persistence was 24 hours (range 2-144 hours). The most common adverse events reported were catheter obstruction (n=6) and leakage at the insertion site (n=4).

### **Conclusions:**

Peritoneal catheters can be inserted for management of peritoneal effusion. Indications include stabilisation and conservative management of uroabdomen, and autotransfusion. They can often be placed with minimal or no sedation and adverse events appear mild.



**P013 / #501**

**Topic:** *AS07 Dentistry*

**EVERY LIFE MATTERS: DOGS BORN WITH CLEFT PALATE ASSOCIATED OR NOT WITH CLEFT LIP SHOULD NOT BE EUTHANASED**

R.I. Nedelea<sup>1</sup>, A. Marincus<sup>2</sup>, A. Toma<sup>3</sup>, C. Cirdeiu<sup>3</sup>, D. Popa<sup>3</sup>

<sup>1</sup>Dentovet.ro, Veterinary Dentistry, Florești, Romania, <sup>2</sup>Clinica Veterinară Calvaria, Veterinary Dentistry, Cluj-Napoca, Romania, <sup>3</sup>Clinica Veterinara Calvaria, Veterinary Dentistry, Cluj-Napoca, Romania

**Introduction:**

A Cleft palate is an abnormal fissure of the secondary palate. A cleft lip is a defect that affects the primary palate. Congenital cleft palate and cleft lip result from the failure of embryonic structures to fuse. They may be associated, or they may stand alone.

**Objectives:**

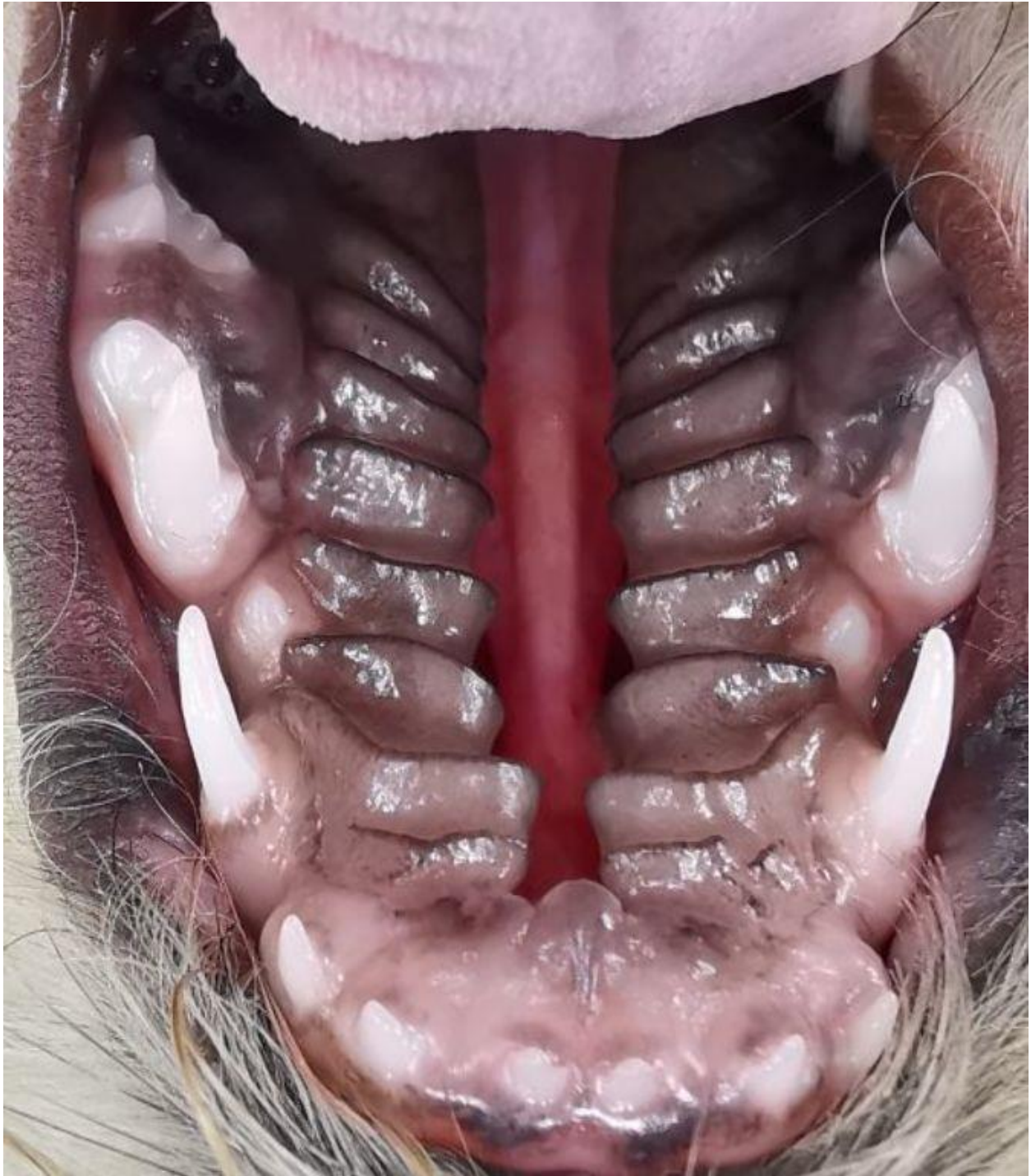This case report aims to increase awareness of the high incidence of euthanasia among puppies born with these defects.

The lack of information is responsible for this.

**Methods:**

A large secondary palate defect involving the hard palate and the soft palate was presented to our clinic. Five months old Yorkshire terrier, 1418 grams, had a congenital communication between the oral and nasal cavities, measuring 6/1 centimetres. Feeding was seriously

affected.



We have performed the overlapping flap technique with an envelope flap proposed by Reiter and Smith in 2005 for the hard palate palatoplasty. For the soft palate closure, we have used the medially positioned flap.

**Results:**

We have obtained a separation between oral and nasal cavity on a 70% of the defect in the first surgical intervention. Therefore, the soft palate will be fully closed, in another surgical intervention, by the age of one. One month weight after surgery was 1600grams, confirming our good results.

**Conclusions:**

Cleft palate associated or not with cleft lip should not be a criterion for euthanising puppies. But, unfortunately, after performing the surgery and exposing our results on social media, we have found out that numerous puppies with this kind of congenital disability were euthanised while they shouldn't be.

**P014 / #502**

**Topic:** *AS07 Dentistry*

## **WHEN CLEAN TEETH AND HALITOSIS IS A BIG WARNING SIGN-AN IMPRESSIVE STICK INJURY OF THE HARD PALATE IN A DOG**

R.I. Nedelea<sup>1</sup>, A. Marincus<sup>2</sup>, A. Toma<sup>2</sup>

<sup>1</sup>Dentovet.ro, Veterinary Dentistry, Florești, Romania, <sup>2</sup>Clinica Veterinara Calvaria, Veterinary Dentistry, Cluj-Napoca, Romania

### **Introduction:**

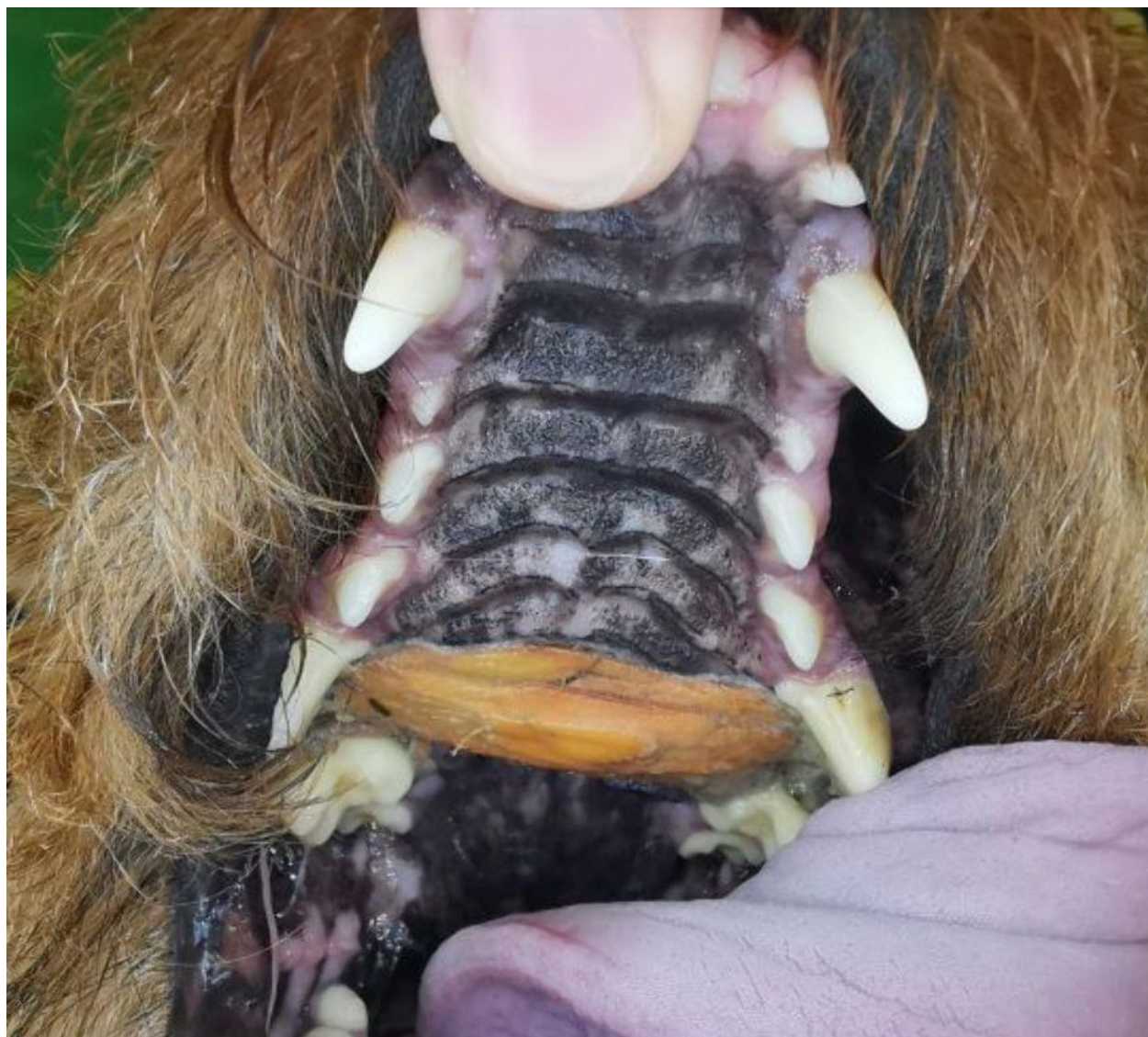
Every day veterinary dentistry practice associates halitosis with periodontal disease. Practitioners often automate these associations missing others seldom, but essential with an impressive evolution, diagnoses.

### **Objectives:**

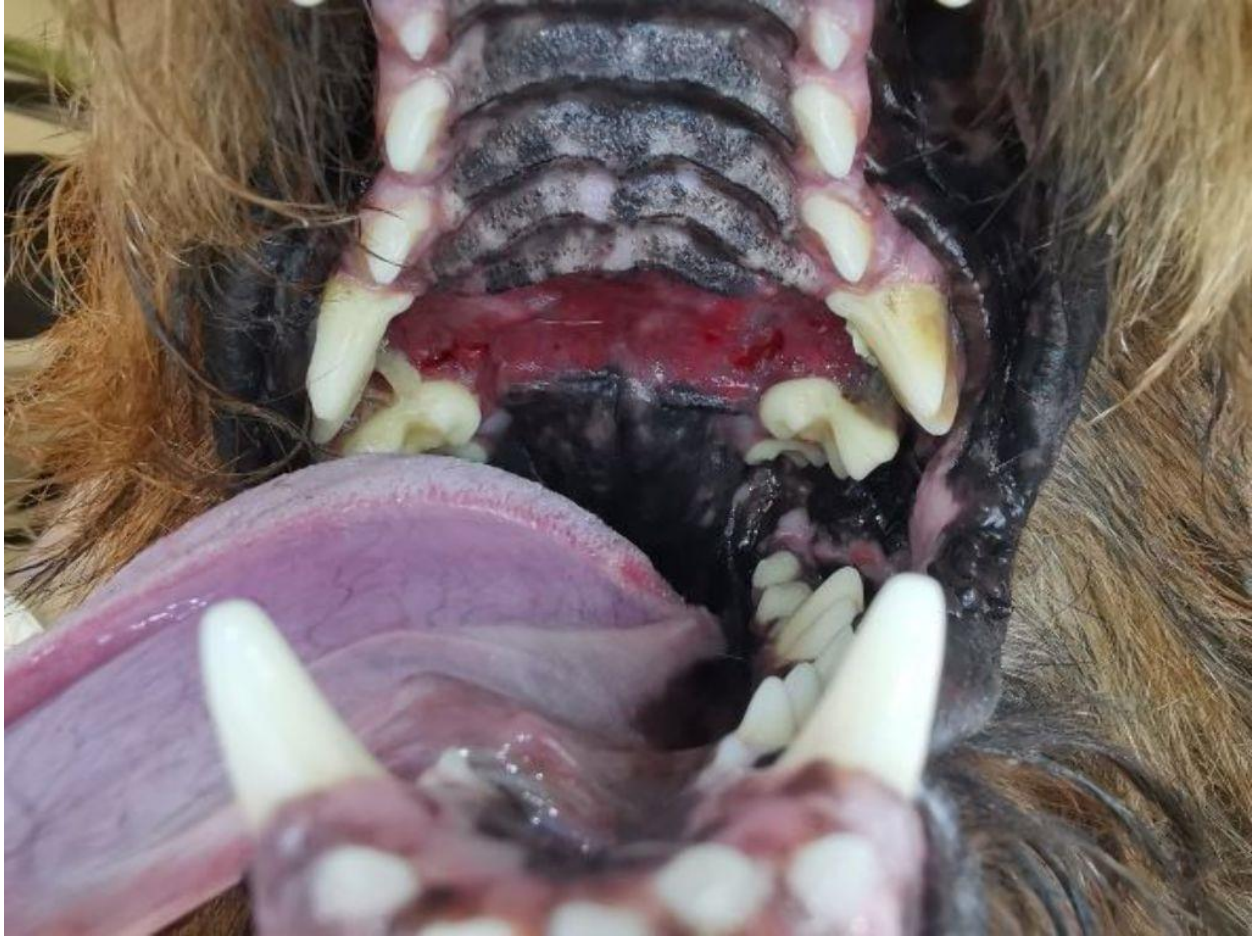The objective of this case report is to remind that the presence of clean teeth is not a sufficient argument for not acting when halitosis is present.

### **Methods:**

A seven years old daschund asked for an appointment for dental cleaning. The teeth were clean. Still, strong halitosis was present. Oral examination under general anaesthesia revealed a stick wedged between the maxillary carnassial teeth a long time ago. The affected palatal mucosa showed no more palatine rugae. Instead, an ulcerative lesion was present with a width of one inch that would cause spontaneous bleeding. Carnassials were moved, and a gap of 4mm was present between carnassials and upper first molars. The new location was achieved a long time before our discovery, as the moved teeth showed no mobility sign. Still, the roots adjacent to the gap were 5 mm exposed in the oral cavity.

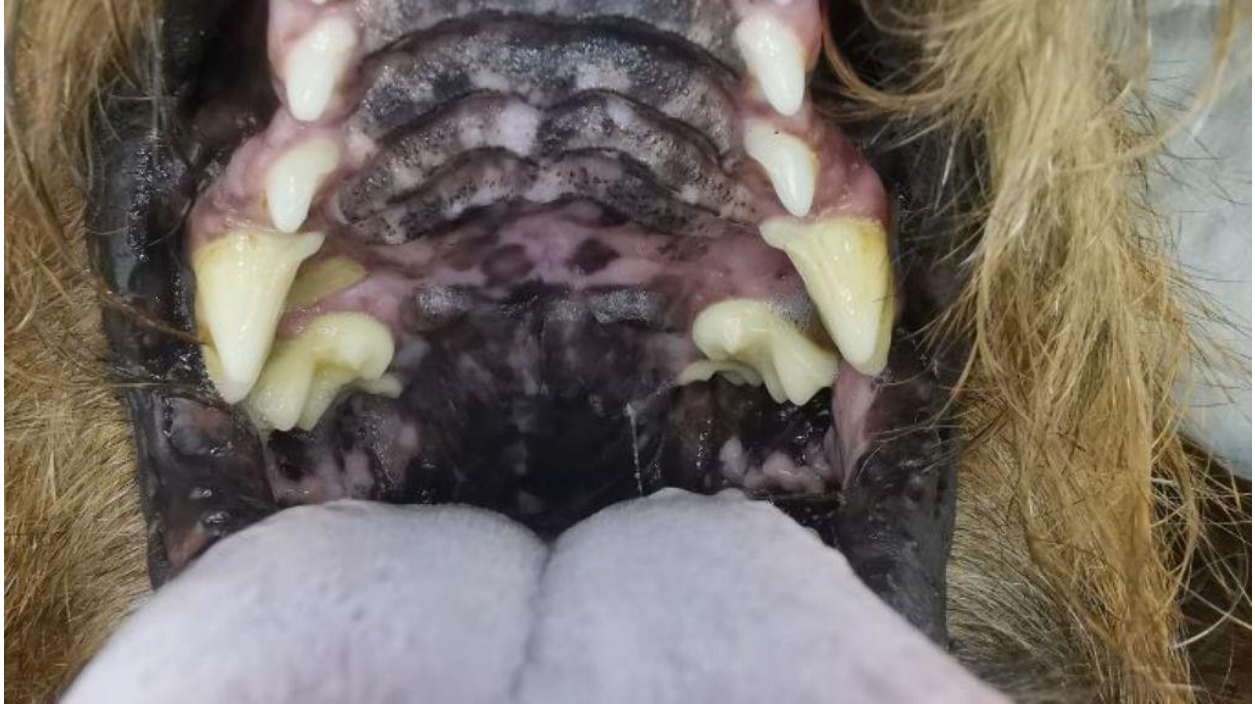





**Results:**

We have obtained complete epithelisation without gaining the palatine rugae in six weeks. We used a gel containing lactoferrin.



### **Conclusions:**

When severe halitosis is present, even though the teeth are clean, one should consider other diagnoses. For example, if the foreign body is removed immediately after sticking, the patient's suffering shows a significant reduction. Our patient was seen by several colleagues before us that would refuse dental cleaning without establishing the cause of halitosis. Continuous education, refreshing information is imperative for all of us.

**P015 / #517**

**Topic:** *AS07 Dentistry*

## **PERIODONTAL DISEASE IN A CARPATHIAN RED-TAIL DEER (CERVUS ELAPHUS)**

R.I. Nedelea<sup>1</sup>, A. Toma<sup>2</sup>, A. Marincus<sup>2</sup>

<sup>1</sup>Dentovet.ro, Veterinary Dentistry, Florești, Romania, <sup>2</sup>Clinica Veterinara Calvaria, Veterinary Dentistry, Cluj-Napoca, Romania

### **Introduction:**

Periodontal disease affects periodontal ligaments, gingiva and the bone surrounding the teeth. It has been reported in humans, small animals (cats and dogs), wild felines. In addition, a case of periodontal disease in Cervidae has been found in Eastern Europe, and for sure, it is not a singular one.

### **Objectives:**

This case report would like to expand the area of affected species by periodontal disease.

### **Methods:**

A red-tail deer refused food for about one month, bit cold metal objects turned her kind behaviour into an aggressive one, lost weight, the coat was still shedding, even though it was full summertime, and experienced pain episodes when it was yawning for minutes.

Oral examination under general anaesthesia revealed an aggressive periodontal disease (PD4), furcation stage 3 (F3), mobility stage 3 (M3), the gingiva was bleeding spontaneously, and severe halitosis was present. In addition, coronal parts of the mandibular incisors were fractured 2-3 mm from the gingiva, with the dental pulp exposed.

### **Results:**

Full mouth extractions were performed in two sessions. No ruminal atony or tympany was reported.

### **Conclusions:**

Periodontal disease is present even in Cervidae. In the wilderness, dental pain leads to no feeding properly, losing weight and becoming a safe prey for the predators. The circle of life in nature starts and ends in its own way. We still have a lot to learn and to understand its rules.



**Topic:** *AS07 Dentistry*

## **LASER-ASSISTED EXCISION OF A LINGUAL RHABDOMYOMA IN A DOG**

A. Tabaran<sup>1</sup>, R.I. Nedelea<sup>2</sup>, A. Toma<sup>3</sup>, A. Marincus<sup>3</sup>

<sup>1</sup>USAMV Cluj-Napoca-Faculty of Veterinary Medicine, Anatomic Pathology, Cluj-Napoca, Romania, <sup>2</sup>Dentovet.ro, Veterinary Dentistry, Florești, Romania, <sup>3</sup>Clinica Veterinara Calvaria, Veterinary Dentistry, Cluj-Napoca, Romania

### **Introduction:**

Reports of rhabdomyomas in extracardiac locations are rare, as most of the rhabdomyomas in dogs have been found in the heart. However, canine rhabdomyomas may be challenging to diagnose from other 'eosinophilic granular cell' tumours by light microscopy only. Precise diagnosis requires immunohistochemistry techniques or/and transmission electron microscopy.

### **Objectives:**

This paper describes laser-assisted excision of a rhabdomyoma. As a sporadic type of benign tumour, we would like to report it, as the last one published was in 1992 by Rivera and Carlton.

### **Methods:**

Laser-assisted excision of a lingual mass, 1,5x1 cm, was performed in a dog. The lingual mass was localized on the left side of the dorsal surface of the caudal portion of the tongue. Laser parameters used were wavelength: 940nm, power 6W, continuous pulse mode, tip diameter 400µm. No sutures were placed as it was made a laser-assisted biological membrane for healing.

### **Results:**

Fourteen days check-up revealed an epithelized surgical plaque. Light microscopy associated with immunohistochemistry diagnosed the tumour as a rhabdomyoma.

### **Conclusions:**

Laser-assisted small excisions on the dorsal surface of the tongue may be left unsutured. Laser-assisted healing with the biological membrane residues in inducing a wide range of cellular effects. Understanding all the cellular changes induced by lasers is the key to predictable success.

Rhabdomyomas may be found in the oral cavity of dogs.

**P017 / #601**

**Topic:** *AS07 Dentistry*

## **CLINICAL EFFICACY OF CANNABIDIOL AS ANALGESIC ADJUVANT IN CATS WITH CHRONIC GINGIVOSTOMATITIS SUBMITTED TO DENTAL EXTRACTIONS**

J. Coelho, M. Silva, A. Reisinho, L. Iglésias, R. Rosa, L. Mestrinho  
Faculdade de Medicina Veterinária, Universidade de Lisboa, Ciisa - Centro De Investigação Interdisciplinar Em Sanidade Animal, Lisbon, Portugal

### **Introduction:**

Feline chronic gingivostomatitis (FCGS) is a highly painful and debilitating oral inflammatory disease associated with chronic pain. Cannabidiol (CBD) is the most well-known non-psychoactive phytocannabinoid, with several recognized therapeutic benefits, namely in the treatment of chronic pain.

### **Objectives:**

This study evaluated the efficacy of a CBD based powder as a post operative analgesic adjuvant in FCGS.

### **Methods:**

A placebo-controlled single blinded study was conducted in a group of 18 cats for 15 days post operatively. Ten cats received CBD powder at a dose interval of 0,8 to 2mg/kg every 12 hours and 8 cats received a placebo powder of similar characteristics. Treatment began 2h before surgery. Clinical assessment, owner evaluation score and stomatitis disease activity index (SDAI) were performed 2 hours before and 15 days after surgery. Composite oral pain scale-canine/feline (COPS-C/F) was assessed at 4 moments starting 2h before induction (T0,4,8 and 24h). Additional analgesic reinforcement to the peri operative protocol was registered as rescue.

### **Results:**

No differences were registered between cases and controls in SDAI and COPS-C/F, although the average number of rescues was superior in controls. Owner evaluation score reduced significantly in the treatment group. No signs to intolerance were registered throughout the treatment time.

### **Conclusions:**

This clinical trial suggests that CBD continuous treatment of 15 days at a dosage interval of 0.5 to 2mg/kg twice daily can increase comfort in FCGS.

**P018 / #481**

**Topic:** *AS08 Dermatology*

## **THE POTENTIAL OF A COMMERCIAL CHROMOGENIC AGAR FOR BACTERIA IDENTIFICATION IN CANINE AND FELINE PYODERMA AND OTITIS EXTERNA**

B. Cugmas<sup>1,2</sup>, M. Avberšek<sup>2</sup>

<sup>1</sup>University of Latvia, Institute Of Atomic Physics And Spectroscopy, Riga, Latvia, <sup>2</sup>Vets4science Ltd, Veterinary Clinic Zamba, Celje, Slovenia

### **Introduction:**

Bacterial skin inflammation (pyoderma) and otitis externa are common dermatological disorders in dogs and cats. Since swab observation under a microscope can only distinguish between cocci and rods, cytology has a limited diagnostic and therapeutic value.

### **Objectives:**

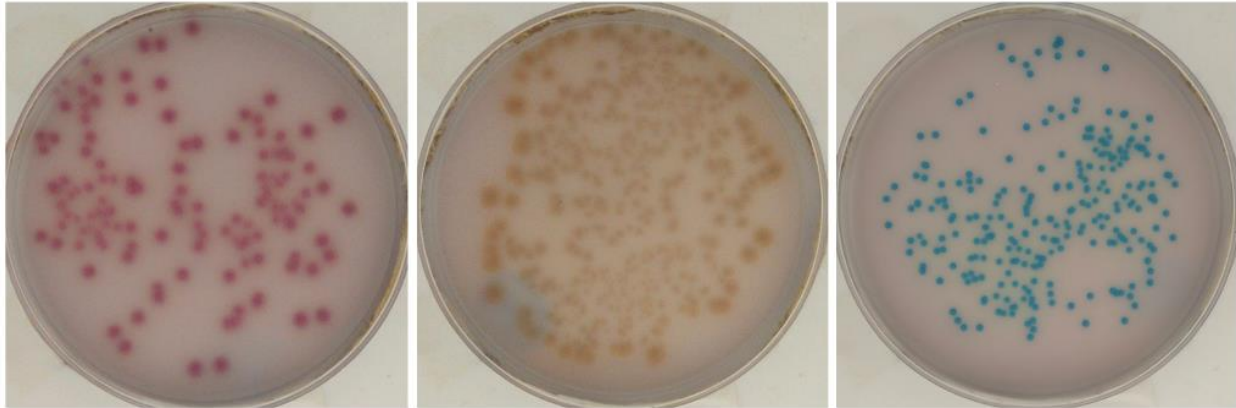
Our study focused on how well veterinary clinicians can identify the most common skin pathogens with a chromogenic agar (UriSelect 4, Bio-Rad Laboratories, Inc., Hercules, CA, USA).

### **Methods:**

Based on previously collected pyoderma and otitis swabs, 26 monoculture isolates were cultivated on UriSelect for 24h. We included *Staphylococcus pseudintermedius* (10 plates), *Staphylococcus felis* (4), *Escherichia coli* (4), *Enterococcus faecalis* (4), and *Pseudomonas aeruginosa* (4). Before the evaluations, three general practitioners received a short tutorial on how selected bacteria, which our study was knowingly limited to, grow on the agar. Additional information (e.g., canine or feline, skin or ear, and cocci or rods) was provided for each sample.

### **Results:**

The accuracy of bacterial species identification was 100 % by all three evaluators. Most bacteria grew in specific colors (Figure 1, *E. coli* – red, *P. aeruginosa* – orange-green with a metallic sheen, *E. faecalis* – blue). Although both *Staphylococcus* exhibited similarly pale colonies, differentiation was possible because bacteria are typically animal-specific. However, agar's accuracy would presumably deteriorate with less common but similarly growing skin pathogens included (e.g., *S. aureus*, *Streptococcus canis*, *Corynebacterium*).

**Conclusions:**

Chromogenic agars are a promising point-of-care test to identify the most common canine and feline skin pathogens.

**P019 / #524**

**Topic:** *AS09 Diagnostic imaging*

## **EVALUATION OF PULMONARY HYPERTENSION IN DOGS WITH HEARTWORM DISEASE USING THE PULMONARY TRUNK TO DESCENDING AORTA DIAMETER RATIO**

J.I. Matos Rivero, Y. Falcón Cordón, S.N. García Rodríguez, N. Costa Rodríguez, E. Carretón Gómez, J.A. Montoya Alonso

University of Las Palmas of Gran Canaria, Internal Medicine, Faculty Of Veterinary Medicine, Research Institute Of Biomedical And Health Sciences (iuibs), Las Palmas de Gran Canaria, Spain

### **Introduction:**

*Dirofilaria immitis* (heartworm) produces pulmonary endarteritis, which chronically leads to pulmonary hypertension (PH) and right-sided cardiac failure. The use of angiography through Computed Tomography (CT) and the measure of the pulmonary trunk to descending aorta diameter ratio (PT:Ao ratio), constitutes a quantitative measure that has already demonstrated an objective diagnosis of PH in dogs, and has improved the diagnostic performance in comparison with echocardiography in human medicine.

### **Objectives:**

The objective was to determine the utility of PT:Ao ratio obtained by CT to stage the severity of PH in heartworm disease.

### **Methods:**

24 heartworm-infected dogs were evaluated. Computed Tomography with intravenous contrast allowed measurement of the PT:Ao ratio according to previous authors. The correlation between the PT:Ao ratio and 4 echocardiographic parameters (tricuspid regurgitation pressure gradient, the ratio of main pulmonary artery diameter to aortic root diameter, right pulmonary artery distensibility index, and the parasite load) were evaluated to determine the presence/absence of PH using the Pearson's correlation coefficient.

### **Results:**

A statistically significant relationship ( $p < 0.01$ ) was observed between the presence or absence of PH  $> 55$ mmHg ( $n=11$  and  $n=13$ , respectively) and the PT:Ao ratio ( $1.88 \pm 0.39$  vs  $1.08 \pm 0.33$ ).

### **Conclusions:**

The results suggest the possibility of using the PT:Ao ratio as a tool to help determine the presence and severity of PH in dogs infected by *Dirofilaria immitis*. This ratio might be useful for the diagnosis, monitoring and prognosis of parasitized animals. Further studies with larger numbers of animals should be carried out.

**Topic:** AS09 Diagnostic imaging

## **EFFECT OF FEMORAL ANGULATION IN DORSAL PLANE ON THE NORBERG ANGLE ASSESSMENT ON HIP RADIOGRAPHS OF DOGS**

P. Franco Gonçalo<sup>1</sup>, S. Pimenta<sup>2,3</sup>, P. Leite<sup>4</sup>, F. Arraz<sup>4</sup>, M. Ferreira<sup>4</sup>, B. Colaço<sup>2,3</sup>, M. Ginja<sup>1,3</sup>

<sup>1</sup>UTAD - University of Trás-os-Montes e Alto Douro, Department Of Veterinary Science, University Of Trás-os-montes And Alto Douro, Vila Real, Portugal, Vila Real, Portugal, <sup>2</sup>UTAD - Universidade de Trás-os-Montes e Alto Douro, Department Of Animal Science, Vila Real, Portugal, <sup>3</sup>UTAD - Universidade de Trás-os-Montes e Alto Douro, Citab - Centre For The Research And Technology Of Agro-environmental And Biological Sciences, Vila Real, Portugal, <sup>4</sup>Neadvance Machine Vision SA, Neadvance Machine Vision Sa, Braga, Portugal

### **Introduction:**

Inappropriate dog positioning on ventrodorsal conventional (VDC) hip radiographs results on poor radiographic technical quality, which may influence the relationship between the femoral head and acetabulum. However, this relationship was not yet established.

### **Objectives:**

To assess the influence of femoral angulation (FA) in NA evaluation.

### **Methods:**

In this study were used 44 VDC hip radiographs (22 dogs). Each dog had two repeated VDC hip views, one with excellent positioning quality and the other with different femoral parallelism (>1 degree). FA was evaluated using the Dys4Vet software, between the long axis of each femur and the long body axis, considering this perpendicular to the line joining the two craniolateral acetabular edges. The NA was also assessed in each hip joint. Difference values in FA and NA obtained in repeated radiographs of each femur and joint were analyzed.

### **Results:**

Both variables had a normal distribution. Thirty-two femurs had different FA >1°, differences ranged from -7.3 to 10.8°, mean±SD 0.6±3.8° and NA ranged from -3.8 to 4.8°, mean 0.59±2.4°, with a Pearson correlation between them of 0.69 (p<0.01) and a regression equation of  $y = 0.434x + 0.328$ , where y represents NA and x FA differences.

### **Conclusions:**

Increased (abduction) and decreased (adduction) of FA resulted in an increment or reduction of NA, respectively. This is especially important to score cases without or with slight HD. The regression obtained allows to correct the NA in radiographs presenting some degree of femoral angulation.

This work was financed by project Dys4Vet (POCI-01-0247-FEDER-046914), co-financed the ERDF through COMPETE2020 and CEECINST/00127/2018UTAD.

**Topic:** AS09 Diagnostic imaging

## RELATIONSHIP BETWEEN THE HIP CONGRUENCE INDEX AND HIP FCI CATEGORIES IN DOGS

D. Moreira Da Silva<sup>1</sup>, S. Pimenta<sup>2,3</sup>, P. Franco Gonçalo<sup>4</sup>, B. Colaço<sup>2,3</sup>, A. Santana<sup>3,5</sup>, M. Ferreira<sup>6</sup>, L. Gonçalves<sup>1</sup>, M. Ginja<sup>3,7</sup>

<sup>1</sup>UTAD - Universidade de Trás-os-Montes e Alto Douro, Department Of Engineering, Vila Real, Portugal, <sup>2</sup>UTAD - Universidade de Trás-os-Montes e Alto Douro, Department Of Animal Science, Vila Real, Portugal, <sup>3</sup>UTAD - Universidade de Trás-os-Montes e Alto Douro, Citab - Centre For The Research And Technology Of Agro-environmental And Biological Sciences, Vila Real, Portugal, <sup>4</sup>UTAD - University of Trás-os-Montes e Alto Douro, Department Of Veterinary Science, University Of Trás-os-montes And Alto Douro, Vila Real, Portugal, Vila Nova de Gaia, Portugal, <sup>5</sup>Lusófona University, Lisbon, Department Of Veterinary Science, Lisboa, Portugal, <sup>6</sup>Neadvance Machine Vision SA, Neadvance Machine Vision Sa, Braga, Portugal, <sup>7</sup>UTAD - University of Trás-os-Montes e Alto Douro, Department Of Veterinary Science, University Of Trás-os-montes And Alto Douro, Vila Real, Portugal, Vila Real, Portugal

### Introduction:

Machine learning, enabling computers to understand images, is a hot topic in medical imaging diagnosis. An early step of this process is based on the annotation of images with key points by humans to teach and train the machines.

### Objectives:

To quantify the acetabular area occupied by the femoral head (AAOFH) and associate it with the grade of canine hip dysplasia.

### Methods:

In this study were used 100 ventrodorsal hip radiographs (200 hip joints). The acetabulum and femoral head were delimitedated using the image polygonal annotation tool, labelme. The acetabular area (AA) and AAOFH were measured. Then, it was calculated the hip congruence index (HCI) dividing AAOFH by AA. The Norberg angle and Fédération Cynologique Internationale (FCI) scoring using five categories (A, B, C, D and E) were also determined to characterize each hip joint.

### Results:

The HCI ranged from 0.08 to 0.85, mean  $\pm$  standard deviation  $0.67 \pm 0.12$ . In FCI categories (number) the mean HCI was: A (75)  $0.75 \pm 0.04$ ; B (66)  $0.69 \pm 0.05$ ; C (29)  $0.64 \pm 0.06$ ; D (17)  $0.49 \pm 0.10$ ; E (13)  $0.38 \pm 0.14$  ( $P < 0.05$ , between all categories in ANOVA Dunnett's Posthoc test). The NA ranged from  $64.6^\circ$  to  $112.4^\circ$ , mean  $101 \pm 7.5^\circ$  and the Pearson correlation between NA and HCI was 0.84 ( $P < 0.05$ ).

### Conclusions:



HCI is directly associated with the degree of canine hip dysplasia and is an annotation methodology recommended in machine learning training for hip dysplasia scoring since it is a variable that adequately represents FCI categories.

This work was financed by project Dys4Vet (POCI-01-0247-FEDER-046914), co-financed the ERDF through COMPETE2020 and CEECINST/00127/2018UTAD.

**Topic:** *AS09 Diagnostic imaging*

## **DIAGNOSIS OF ANAL ATRESIA IN A 55-DAY-OLD MIXED-BREED DOG USING FISTULOGRAPHY AND COMPUTED TOMOGRAPHY SCAN**

M. Molazem<sup>1</sup>, M. Honarjoo<sup>1</sup>, N. Ameri<sup>1</sup>, A. Rajabi Majd<sup>2</sup>

<sup>1</sup>Faculty of Veterinary Medicine, University of Tehran,, Surgery And Radiology, Tehran, Iran, <sup>2</sup>Faculty of Veterinary Medicine, University of Tehran,, Small Animal Internal Medicine, Tehran, Iran

### **Introduction:**

Atresia ani is a congenital defect of the anorectum, resulting in anal canal closure and an abnormal routing of feces; it is rarely reported in dogs with females more likely to be affected than males.

Atresia ani is caused by failure of the urorectal fold to completely separate the primitive cloaca, or by failure of the anal membrane opening after anal genesis and has four anatomic types.

Another anatomic abnormality associated with atresia ani is urethrorectal fistula with unknown incidence and predisposition.

### **Objectives:**

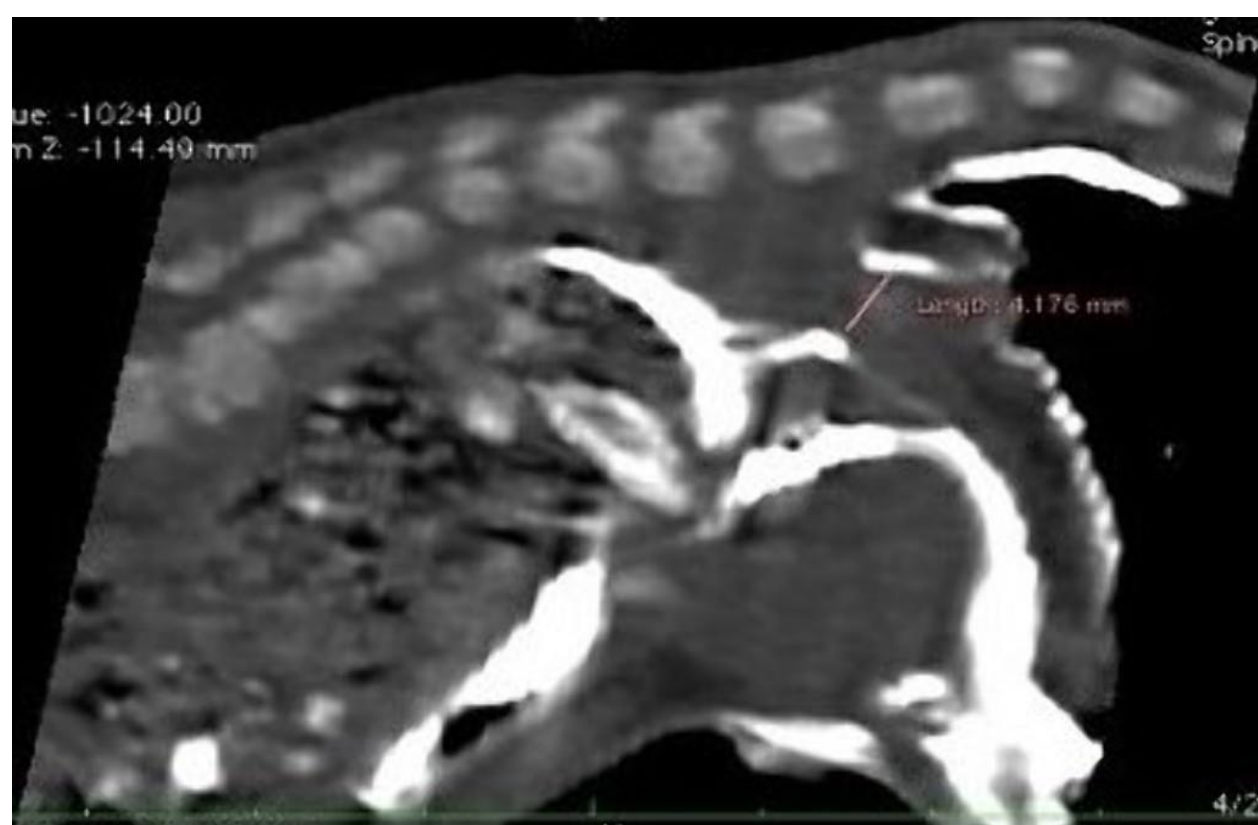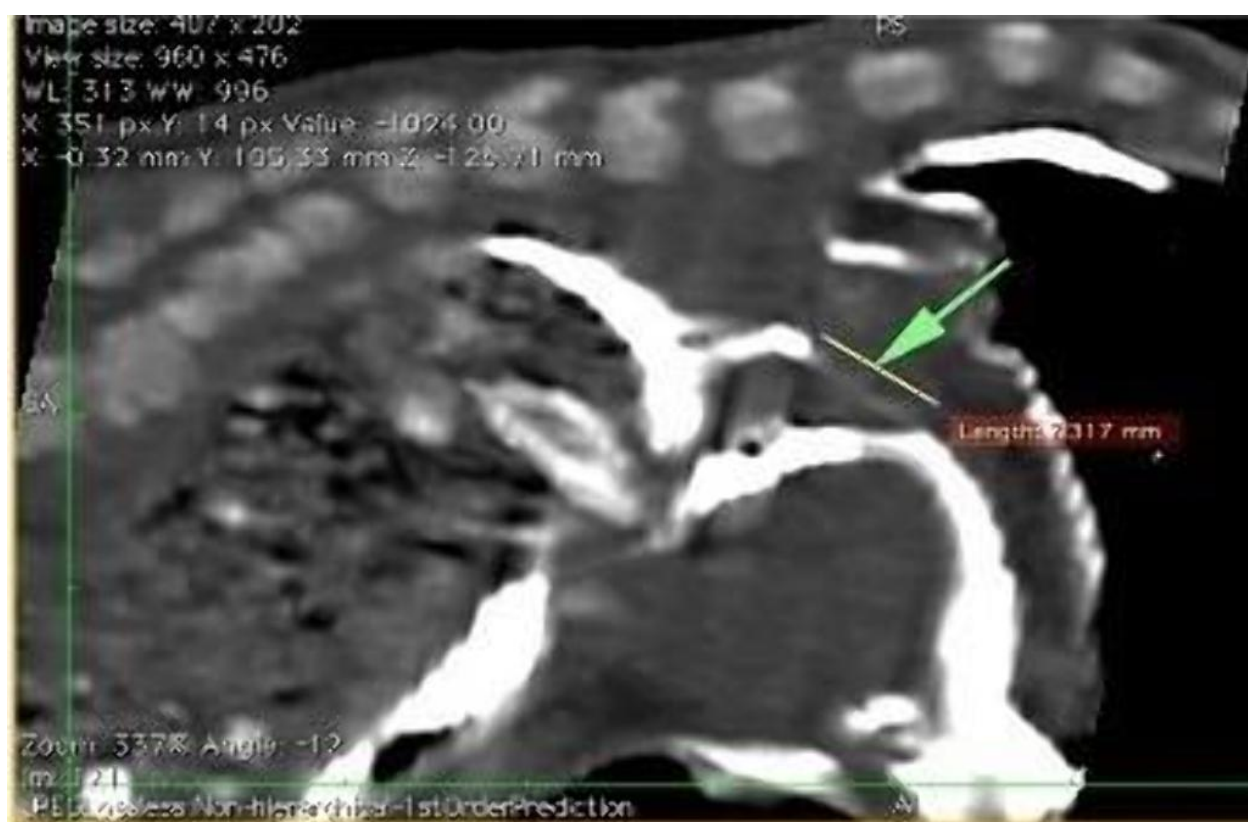A 55-day-old mixed-breed dog presented with chief complaint of retention of feces, distention of abdomen, absence of an anal opening and depression. In clinical examination, anal atresia was suspected.

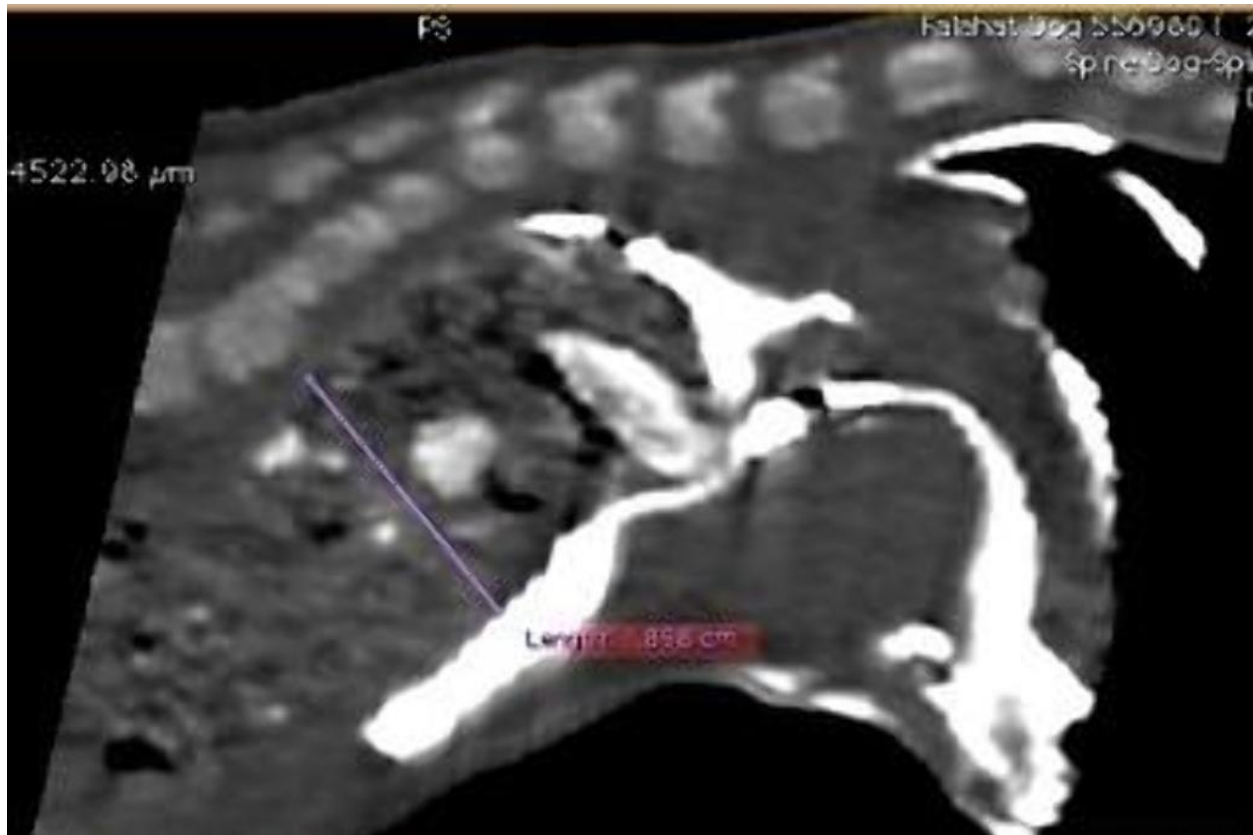### **Methods:**

Perineal CT using visipaque ionic contrast medium administered through the anus and vagina in retrograde fashion.

The CT findings:

Caudal part of the tail is agenesis. Caudal end of colon is dead and stands almost 5 mm cranial to the rectal fistula by a 1.5 cm round soft tissue. Colon is completely filled and distended with formed feces. There is an abnormal communication (~7.5 mm) between the ventro-distal aspect of the caudal dead end of the colon and the perineal urethra.





### Results:

In 2D and 3D images of CT scan, type III anal atresia with rectovaginal fistula was confirmed.

### Conclusions:

Despite the high mortality rate of this congenital abnormality, Early diagnosis of this disease can greatly reduce mortality. CT scan examination with fistulography shows a good method for early diagnosis and preplanning of surgical treatment.

**P023 / #599**

**Topic:** *AS09 Diagnostic imaging*

## **A CASE STUDY OF CARDIAC TAMPONADE IN A DOMESTIC SHORT HAIR MALE CAT.**

D. Noviana, J. Elviyanti, R. Hidayat

Faculty of Veterinary Medicine, IPB University, Clinic Reproduction And Pathology, Bogor, Indonesia

### **Introduction:**

Cats are one of the most popular pets in the world today. One of the main causes of the risk of sudden death in cats is heart disease.

### **Objectives:**

This case study aims to describe the incidence of cardiac tamponade in a 2-year-old domestic short hair male cat diagnosed using echocardiography at IPB University Veterinary Teaching Hospital.

### **Methods:**

The echocardiography modes performed in the patient were two-dimensional Brightness-mode (B-mode) echocardiography, Motion-mode (M-mode), and color flow doppler echocardiography.

### **Results:**

B-mode examination showed pericardial effusion and left atrial enlargement. M-mode examination showed an increase in the thickness of the inter-ventricular septa-diastole, left ventricle posterior wall-diastole, and left ventricle posterior wall-systole. Color flow doppler examination did not show any regurgitation or turbulence in the atrio-ventricular and semilunar valves.

### **Conclusions:**

These results indicate the occurrence of cardiac tamponade in a male domestic short hair cat. The results show normal valve conditions.

**P024 / #628**

**Topic:** *AS09 Diagnostic imaging*

## **DIAGNOSIS OF INTRACRANIAL EPIDERMOID CYSTS IN A 6-YEAR-OLD MIX CAVALIER BREED DOG USING MAGNETIC RESONANCE IMAGING**

M. Molazem<sup>1</sup>, A. Salimi<sup>1</sup>, N. Ameri<sup>1</sup>, A. Rajabi Majd<sup>2</sup>

<sup>1</sup>Faculty of Veterinary Medicine, University of Tehran,, Surgery And Radiology, Tehran, Iran, <sup>2</sup>Faculty of Veterinary Medicine, University of Tehran,, Small Animal Internal Medicine, Tehran, Iran

### **Introduction:**

Intracranial epidermoid cysts are rare, benign, congenital space occupying lesions develop following aberrant inclusion of non-neural ectoderm during neural tube closure or invagination of secondary neural vesicles.

These cysts have been reported sporadically in dogs and are invariably found in caudal fossa mostly within fourth ventricle.

### **Objectives:**

A 6-year-old mix cavalier breed was presented with ataxia, multiple incidence of seizures and dullness, no abnormality has been found in radiography so patient has referred for MRI.

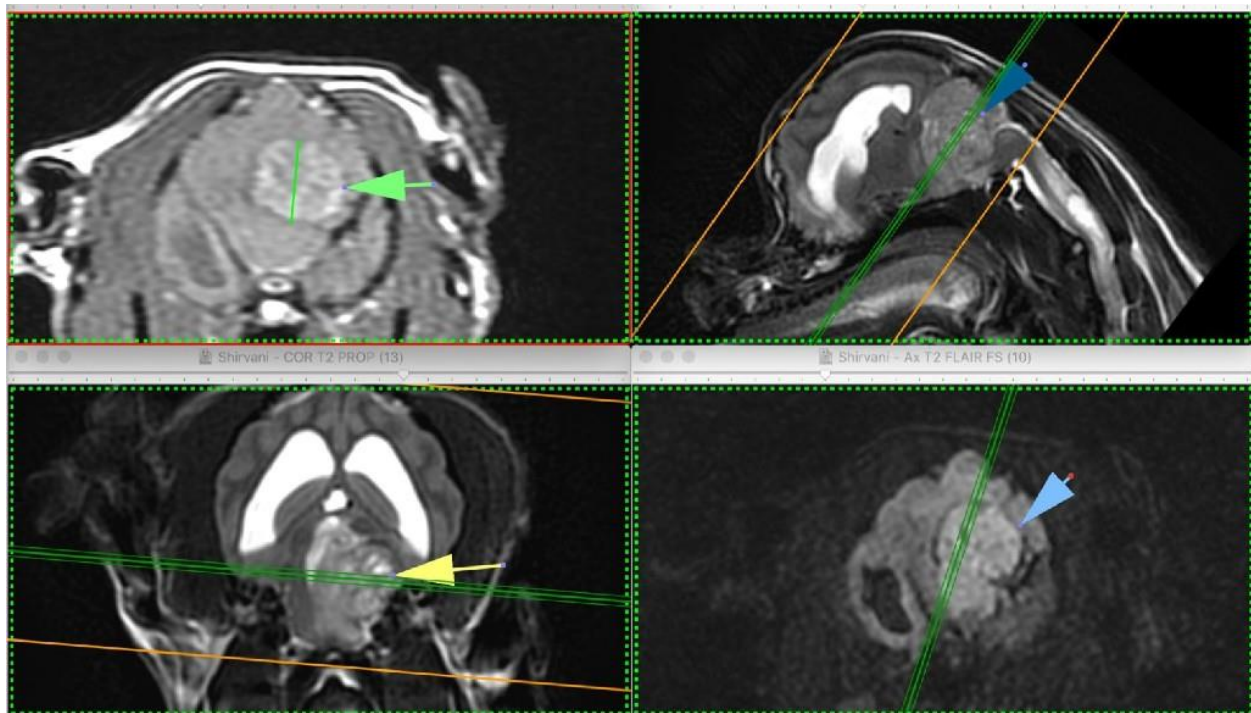
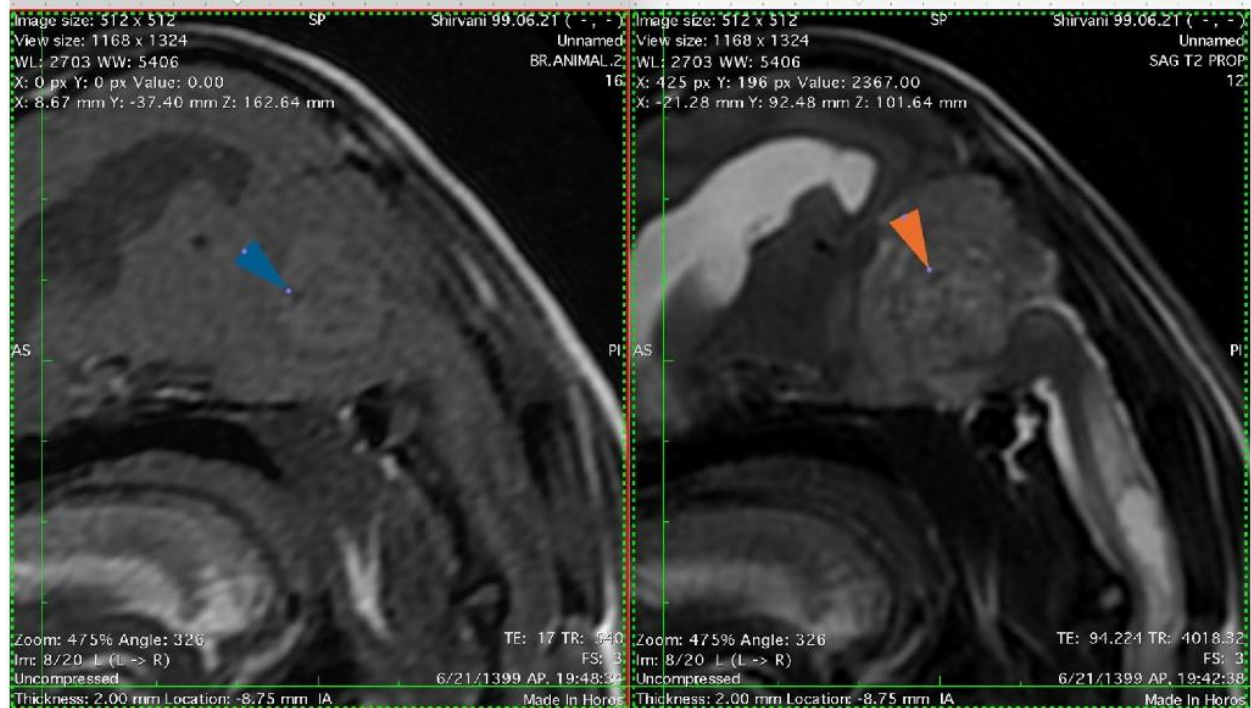
### **Methods:**

MRI revealed a well-demarcated, large ovoid-like lesion in the caudal fossa at the level of fourth ventricle. Lesion extended from dorsal part of medulla displacing cerebellum rostr dorsally.

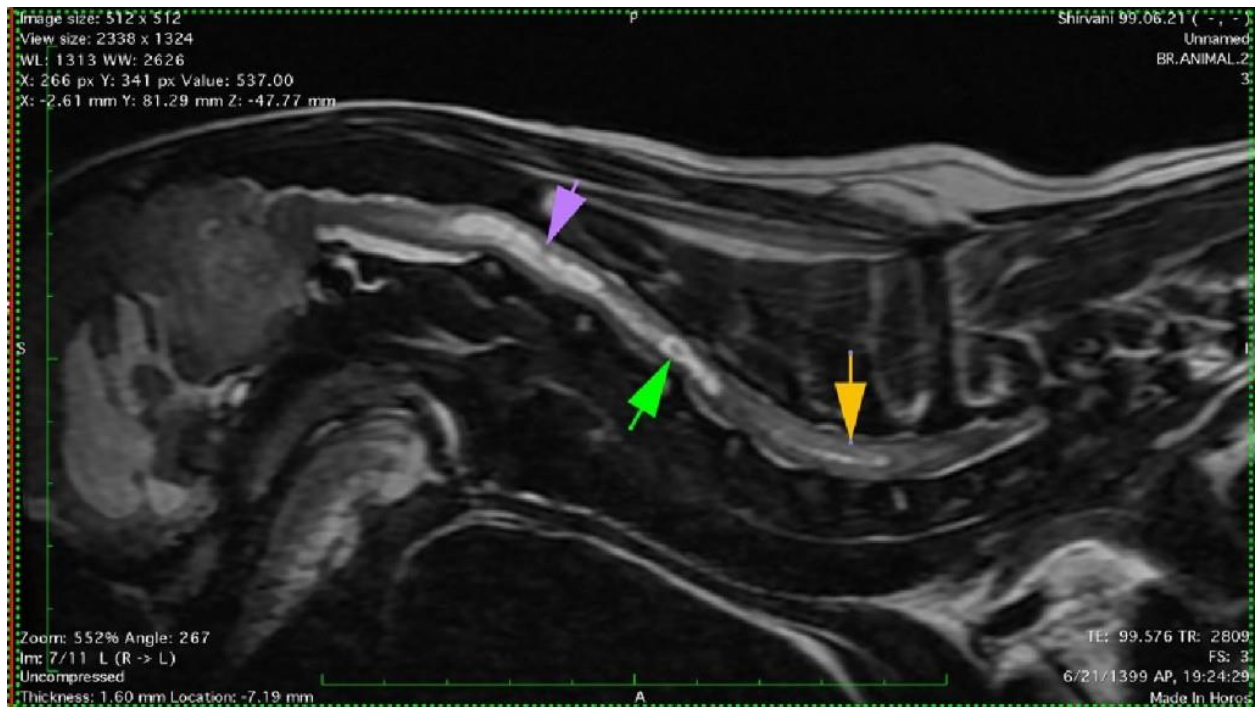
The bulk of the mass arose from the region of the fourth ventricle close to the left cerebellopontine angle.

The signal within the interior of the lesion has a heterogeneous predominantly hyperintense signal on T1w, T2w and T2\* w sequences relative to gray matter. FLAIR shows multifocal fluid attenuating foci. Lesion is 1.6 cm in diameter. Mass has a mild peripheral edema.

There is diffuse irregular intramedullary lesion in cervical and thoracic spine showing fluid signal intensity. Lateral and 3<sup>rd</sup> ventricles are dilated, symmetrically as well as mesencephalic aqueduct. Trigeminal cisterna is distended.







## Results:

There are Large space occupying lesion within the fourth ventricle associated with mild peripheral vasogenic intra-axial edema, obstructive hydrocephalus and diffuse syringomyelia in cervical and thoracic spine.

## Conclusions:

Epidermoid cysts are occasionally an incidental finding at necropsy, euthanasia recommended due to progressive signs and also low life quality of the patient. Epidermoid cyst had confirmed after necropsy.



**Topic:** *AS09 Diagnostic imaging*

## **ELASTOGRAPHIC FINDINGS OF THE SPLEEN IN DOGS WITH VISCERAL LEISHMANIASIS**

C. Dadalto<sup>1</sup>, S. Bonatelli<sup>1</sup>, V. Camprigher<sup>2</sup>, I. Souza Marques<sup>1</sup>, S. Garcia<sup>3</sup>, S. Rahal<sup>1</sup>, J. Silva<sup>1</sup>, M. Mamprim<sup>1</sup>

<sup>1</sup>• São Paulo State University (Unesp), School of Veterinary Medicine and Animal Science, Botucatu- Brazil, Department Of Veterinary Sugery And Animal Reproduction, Botucatu, Brazil, <sup>2</sup>Centro de Controle de Zoonoses, Ccz, Bauru, Brazil, <sup>3</sup>Ribeirão Preto Medical School, University of São Paulo, Departament Of Pathology, Fmrp-usp, Ribeirão Preto, Brazil

### **Introduction:**

Dogs naturally infected with visceral leishmaniasis (VL) may be clinically healthy that may lead to a delay in diagnosis. The spleen is one of the lymphoid organs with the greatest involvement in the pathogenesis of Canine VL because it is a site of parasite replication, which causes diffuse granulomatous lesions of the parenchyma with macrophages infected.

### **Objectives:**

To describe the elastographic findings observed in the splenic parenchyma of dogs naturally infected with VL to assist in the early diagnosis of this disease.

### **Methods:**

B-mode ultrasound examination and Strain elastographic assessment of the splenic parenchyma were performed in 36 symptomatic dogs tested positive for VL, in prospective study. The degree of tissue deformation was based on a qualitative chromatic scale, designating green with high elastic tension (soft), red with low tension (hard), and blue with intermediate tension. The elastographic images were subjectively classified and graded in scores (Tan et al. 2010).

### **Results:**

The splenic parenchyma showed a predominant score of 3 in 47.22% of the dogs (Fig. 1a) that corresponded to a tissue with intermediate elasticity tending to stiff, followed by a score of 4 (stiff) in 27.7% (Fig. 1b). None of the dogs had a score of 1 (soft).

### **Conclusions:**

Splenic elastographic evaluation with the Strain technique in dogs with VL demonstrated colorimetric characteristics of hard tissue parenchyma. Thus, the splenic parenchyma with rigid elastographic characteristics should be considered in the differential diagnosis VL in an endemic region.

**Acknowledgements :** We are grateful to FAPESP (2018/21048-5).

**Topic:** *AS09 Diagnostic imaging*

**DIAGNOSIS OF SECOND-DEGREE WENCKEBACH TYPE AV BLOCK IN A GOLDEN RETRIEVER DOG WITH DILATED CARDIOMYOPATHY**

N. Utami<sup>1</sup>, D. Noviana<sup>2</sup>, F. Senja Murtiningrum<sup>3</sup>, R. Wulansari<sup>1</sup>, K. Dahlan<sup>4</sup>, M. Silalahi<sup>5</sup>  
<sup>1</sup>IPB University, Clinic, Reproduction, Pathology, Bogor, Indonesia, <sup>2</sup>Faculty of Veterinary Medicine, IPB University, Clinic Reproduction And Pathology, Bogor, Indonesia, <sup>3</sup>Faculty of Veterinary Medicine IPB University, Clinic, Reproduction, And Pathology, Bogor, Indonesia, <sup>4</sup>IPB University, Faculty Of Math And Science, Jawa Barat, Indonesia, <sup>5</sup>BATAN, Pstbm, Tangerang Selatan, Indonesia

**Introduction:**

Atrioventricular block (AVB) occurs when conduction of the cardiac impulse is interrupted in the region of the AV node, the AV bundle, or all bundle branches. AVB is usually associated with heart diseases, especially myocardial disorders including hypertrophic cardiomyopathy (HCM), dilated cardiomyopathy (DCM), etc.

**Objectives:**

To determine the definitive diagnosis of heart disease in dog with thorax radiography, echocardiography, and electrocardiography

**Methods:**

A-11-years-old Golden Retriever dog that presented with intermittent coughing was evaluated using thorax radiography, echocardiography and electrocardiography. The radiography was taken with right lateral recumbency and ventrodorsal views. The echocardiography was performed with right parasternal and left apical views using phased-array probe, with frequency 5.3 MHz. The electrocardiography was taken with 5 lead electrode placement.

**Results:**

The thorax radiogram showed enlargement of the heart size. The two dimensional Brightness-mode echocardiography showed thickening of mitral valve. The Motion-mode echocardiography showed increase of left ventricle internal dimension (LVID), and decrease of left ventricle posterior wall (LVPW), ejection fraction (EF), and fractional shortening (FS). The ratio of left atrial appendage-sistole (LAAs) with aortic diameter-diastole (AoDd) was change to 1.1 : 1. The electrocardiogram showed irregular heart rhythm, prolonged with progressive lengthening of the PR interval and deep S waves.

**Conclusions:**

Based on thorax radiography, echocardiography, electrocardiography evaluation, the dog diagnosed with endocardiosis, mild left atrial enlargement, dilated cardiomyopathy, sinus

arrhythmia, AV block 1st degree and AV block 2nd degree type Mobitz I or Wenckebach-type block.

**Topic:** *AS09 Diagnostic imaging*

## **COMPUTED TOMOGRAPHIC FINDINGS IN THE LUNGS OF DOGS NATURALLY INFECTED BY VISCERAL LEISHMANIASIS**

S. Bonatelli<sup>1</sup>, C. Dadalto<sup>1</sup>, A. Belotta<sup>1</sup>, S. Rahal<sup>1</sup>, V. Camprigher<sup>2</sup>, I. Souza Marques<sup>1</sup>, S. Garcia<sup>3</sup>, J. Silva<sup>1</sup>, M. Mamprim<sup>1</sup>

<sup>1</sup>• São Paulo State University (Unesp), School of Veterinary Medicine and Animal Science, Botucatu- Brazil, Department Of Veterinary Sugery And Animal Reproduction, Botucatu, Brazil, <sup>2</sup>Centro de Controle de Zoonoses, Ccz, Bauru, Brazil, <sup>3</sup>Ribeirão Preto Medical School, University of São Paulo, Departament Of Pathology, Fmrp-usp, Ribeirão Preto, Brazil

### **Introduction:**

The organs of the mononuclear phagocytic system are frequently involved by canine visceral leishmaniasis (VL). However, there is evidence that other organs can be affected. In human patients, pulmonary involvement is rare and occurs in immunosuppressed patients. On the other hand, studies of the lung pattern in VL are lacking in dogs.

### **Objectives:**

To describe the CT findings of the lungs in dogs positive and symptomatic for VL.

### **Methods:**

CT exams were performed in 35 cadavers of dogs with VL from a Zoonosis Control Center, in the prospective study. All animals were placed in left lateral decubitus for standardizing of the pulmonary atelectasis and stasis due to decubitus. Before image acquisition, the dog's lungs were inflated with an endotracheal tube inserted via tracheostomy and manual resuscitator. Images were acquired by using 2-mm-thick sections at 2 mm increments (2x2), 120 kVp and 130 mAs by specific windowing. CT images were evaluated according to the method described by Masseau and Reinero (2019).

### **Results:**

All dogs presented ground-glass opacity and peribronchovascular that showed varying degrees. However, 51.42% of the dogs had a moderate degree. Linear, nodular and parenchymal band opacifications were also observed in the lungs, as well as bronchial thickening and dilation.

### **Conclusions:**

The CT appearance of the lungs of symptomatic dogs with VL were similar to those described for LV in humans. Thus, involvement of thoracic organs by canine VL must be considered in the differential diagnosis in endemic areas.

Acknowledgements

We are grateful to FAPESP for the financial support (2018/21048-5) and CNPQ.

**P028 / #661**

**Topic:** *AS09 Diagnostic imaging*

## **POTENTIAL ROLE OF THE COMPUTED TOMOGRAPHY FOR DETECTION OF REPRODUCTIVE TRACT DISEASE IN A RED-FOOTED TORTOISE**

J. Silva, S. Rahal, R. Ichikawa, M. Mamprim

• São Paulo State University (Unesp), School of Veterinary Medicine and Animal Science, Botucatu- Brazil, Department Of Veterinary Surgery And Animal Reproduction, Botucatu, Brazil

### **Introduction:**

The causes of egg retention and follicular stasis are not fully known in chelonians but may be related to nutritional deficiencies, hypocalcemia, and inadequate management. If the problem persists, a yolk coelomitis, or oviductal rupture causing secondary coelomitis may occur. However, the clinical signs can be non-specific.

### **Objectives:**

To describe the importance of CT findings in the diagnosis of reproductive tract disease in a tortoise from South America.

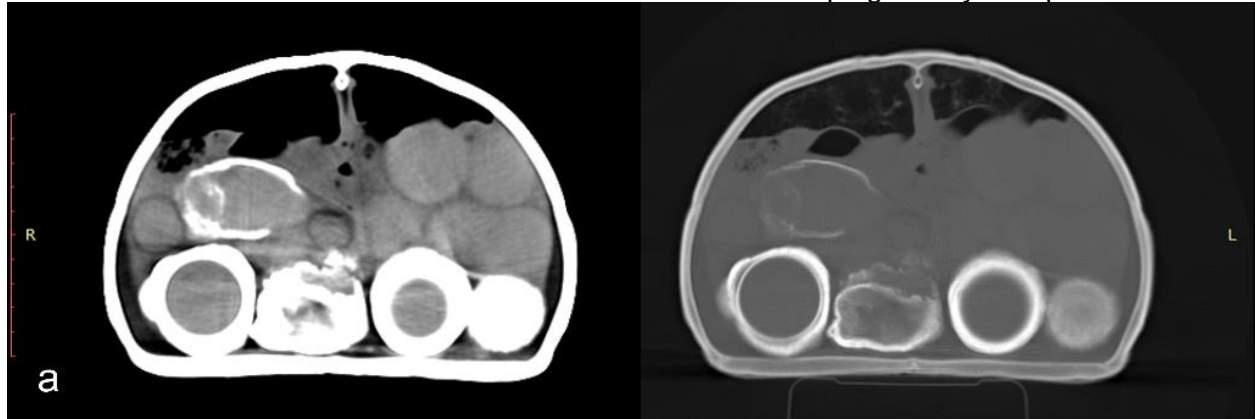
### **Methods:**

A case study, about a 15-year-old red-footed tortoise (*Chelonoidis carbonarius*) was presented to a Center for Medicine and Research in Wild Animals due to frequent contractions in the cloaca region and tail raised. Complete blood count (CBC) and blood biochemistry were done. Imaging studies included radiography and CT of the coelomic cavity.

### **Results:**

CBC revealed an increase in the heterophils, Concentrations of calcium, phosphorus, triglycerides, and cholesterol were found elevated. The radiographic revealed presence of mineralized eggs in the uterus. The eggshells were thick and irregular, suggesting rupture. CT scan verified thick, irregular, and discontinuous eggshells, confirming the rupture(a). Other findings included increased mesenteric density and egg-related coelomitis. Follicles of different sizes (1.53 to 3.59cm) with a density of 88HU were also seen. Celiotomy by plastrotomy showed rupture of the oviduct that was friable, leakage of egg contents into the coelomic cavity,

and adhesions of some follicles to the coelomic membrane. Salpingectomy was performed.



### **Conclusions:**

CT allowed to confirm the diagnosis in this case and may be considered an important tool for evaluating reproductive tract in turtles.

Acknowledgements : We are grateful to FAPESP (2019/01711-4).

## **ULTRASONOGRAPHIC EVALUATION OF THE LIVER, GALLBLADDER, AND SPLEEN IN TOCO TOUCANS**

J. Silva, S. Rahal, L. Rolim, R.A. Gonçalves, M. Mamprim

• São Paulo State University (Unesp), School of Veterinary Medicine and Animal Science, Botucatu- Brazil, Department Of Veterinary Surgery And Animal Reproduction, Botucatu, Brazil

### **Introduction:**

In general, diseases involving the spleen, liver, and gallbladder have nonspecific clinical signs. Thus, imaging diagnosis modalities, such as ultrasound examination, are valuable to complement the physical and laboratory evaluation.

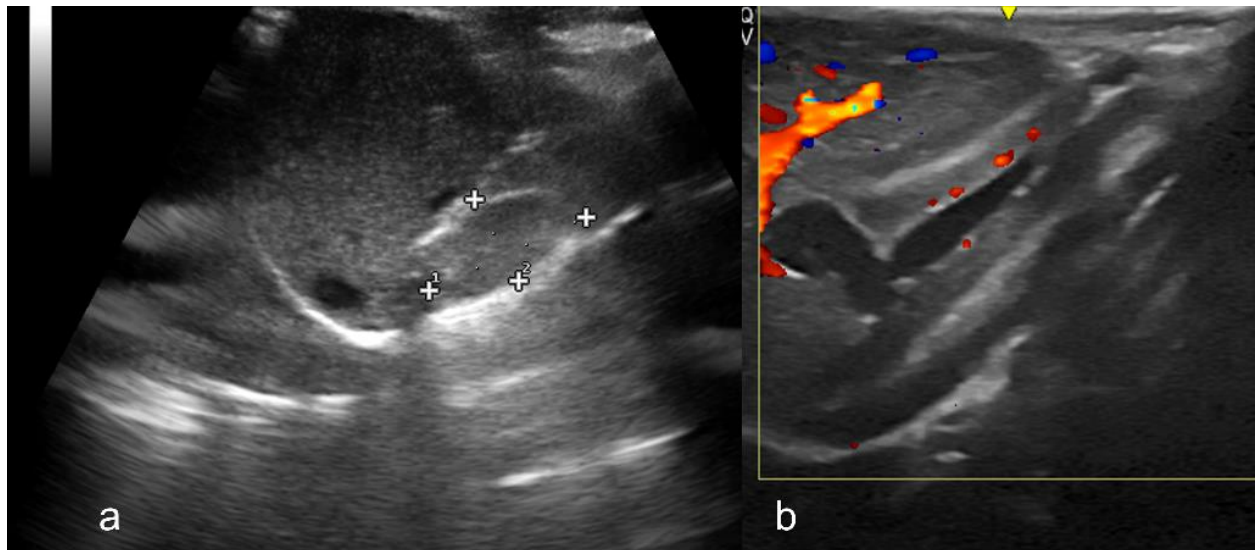
### **Objectives:**

To perform an ultrasonographic evaluation of the liver, gallbladder, and spleen in healthy toco toucans.

### **Methods:**

Ten adult toco toucans (*Ramphastos toco*), weighing 650 grams were enrolled in the study. Bi-dimensional images were obtained of the liver, gallbladder, and spleen, to prospective study. The topography, morphological features, and ultrasound appearance were analyzed.

### **Results:**



Two hepatic lobes were identified (left and right), while the right lobe was larger than the left one. The liver parenchyma had a finely granulated echotexture (Fig a) with echogenicity greater



than that of the splenic and renal parenchyma. The gallbladder was examined as an elongated tubular structure with homogeneous anechoic content showing a low density, and thin and regular walls. The gallbladder(fig b) resembled a square root symbol ( $\sqrt{\phantom{x}}$ ) or a pipe and had proximity with the right hepatic lobe. The spleen had an oval shape ( FIG a +caliper), homogeneous echotexture, echogenicity ranging from hypogenic to isoechogenic in relation to the liver parenchyma.

### **Conclusions:**

Topographic and morphological anatomical studies of the coelomic structures of birds are important for proper assessment and interpretation of imaging exams since facilitating organ location and helping to detect possible disorders.

### **Acknowledgements**

We are grateful to FAPESP (2019/01711-4).

## EVALUATION OF THE KIDNEYS IN TOCO TOUCANS USING THREE IMAGING METHODS

J. Silva, S. Rahal, W. Lima, M. Mamprim

• São Paulo State University (Unesp), School of Veterinary Medicine and Animal Science, Botucatu- Brazil, Department Of Veterinary Sugery And Animal Reproduction, Botucatu, Brazil

### Introduction:

For the evaluation and diagnosis of kidney disease in birds, knowledge of the anatomy of these species is necessary. However, studies about the normal imaging features of kidneys in birds are still few.

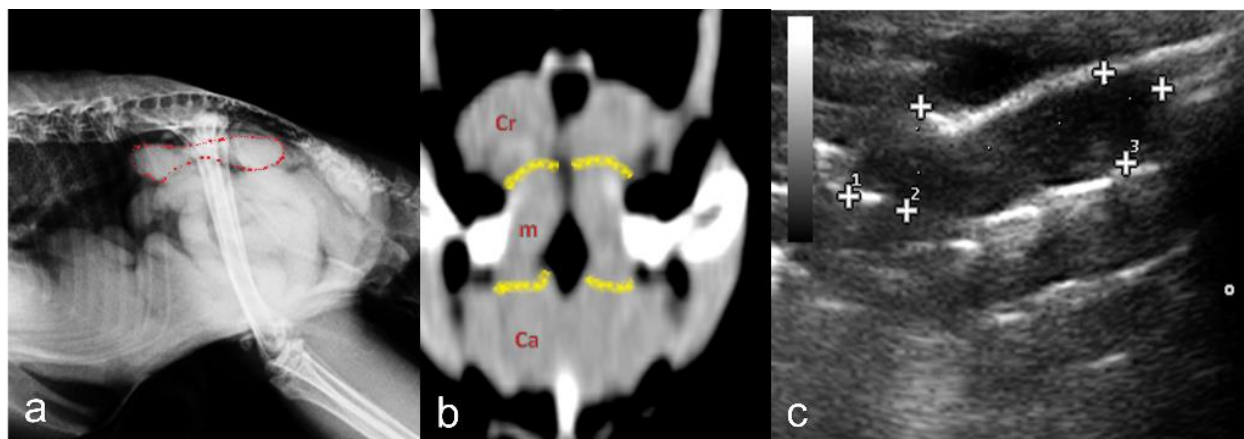
### Objectives:

To describe the characteristics of the kidneys in toco toucan (*Ramphastos toco*) by using three imaging exams.

### Methods:

Thirteen adult toco toucans (*Ramphastos toco*), weighing approximately 650 grams were used, prospective study. The kidneys were evaluated by plain radiographs, computed tomography (CT), and ultrasound exams.

### Results:



The radiographic images showed the right and left kidneys superimposed in the lateral projection. The cranial limit of the kidney was the first sacral vertebra and its caudal limit at the end of the synsacrum. The kidneys could not be evaluated in the ventrodorsal view due to the overlapping of the intestinal loops. CT allowed the visualization of three lobes (cranial, middle, and caudal). The cranial renal lobe was larger compared to the middle and caudal lobes. The kidneys had homogeneous parenchyma and soft tissue density (HU: 40-60), positioned into close contact with the synsacrum. On ultrasonographic examination, the kidneys presented

predominantly hypoechoic parenchyma. The echogenicity ratio was different from mammals (Liver > Spleen > Kidney) with slightly heterogeneous echotexture, without corticomedullary differentiation.

**Conclusions:**

Radiographic examination was ideal for the evaluation of the kidney size, CT allowed a detailed assessment of the renal parenchyma, and ultrasound presented some limitations for evaluating the kidneys due to their location.

**Acknowledgements**

We are grateful to FAPESP (2019/01711-4).

**P031 / #588**

**Topic:** *AS10 Endocrinology*

## **INSULIN, INSULIN SENSITIVITY INDICES, LEPTIN, AND ADIPONECTIN BETWEEN DIABETIC CATS IN REMISSION AND HEALTHY CONTROL CATS**

S. Gottlieb<sup>1</sup>, J. Rand<sup>1,2</sup>, S. Anderson<sup>3</sup>

<sup>1</sup>The University of Queensland, School Of Veterinary Science,, Gatton, Australia, <sup>2</sup>Australian Pet Welfare Foundation, N/a, Fig Tree Pocket, Australia, <sup>3</sup>The University of Queensland, School Of Biomedical Sciences, St Lucia, Australia

### **Introduction:**

Cats in diabetic remission have been demonstrated to have significant differences in several key metabolites compared to control cats. Although diabetic cats are known to be insulin resistant, there are no reports in the literature of insulin sensitivity in cats in diabetic remission and if it predicts relapse.

### **Objectives:**

To identify differences in insulin, adiponectin, leptin, leptin:adiponectin ratio, and insulin resistance between cats in diabetic remission and healthy cats, and whether these hormones are predictors of diabetic relapse; secondly to determine if these hormones were associated with metabolic variables known to differ between groups; thirdly, if any hormonal or metabolomics variables were associated with measures of insulin resistance.

### **Methods:**

Twenty cats in diabetic remission for a median of 101 days, and 21 healthy matched control cats. Following a 24 hour fast, a fasted blood glucose concentration was measured, and blood sample taken for hormone (insulin, leptin, adiponectin) and metabolomic (GCMS and LCMS) analysis. A simplified IVGGT (1g glucose/kg) was performed 3hr later. Cats were monitored for diabetes relapse for at least 9 months (270 days)

### **Results:**

Cats in diabetic remission had significantly higher glucose and insulin levels, as well as decreased insulin sensitivity as demonstrated by an increase in HOMA and decrease in QUICKI and Bennett indices. Leptin was also significantly increased, though there was no difference in adiponectin (or adiposity). There were significant correlations between insulin sensitivity indices, leptin and some metabolites and differences between remission and control cats, but none were predictors of relapse.

### **Conclusions:**

Cats in diabetic remission are insulin resistant.

**P032 / #591**

**Topic:** *AS11 Exotics*

**LOWER URINARY TRACT DISEASE IN GUINEA PIGS (CAVIA PORCELLUS), A 14 YEARS RETROSPECTIVE STUDY (2004-2018)**

S. Azevedo<sup>1</sup>, B. Omalley<sup>2</sup>, H. Moran<sup>2</sup>, C. Greene<sup>2</sup>, F. Queiroga<sup>3</sup>

<sup>1</sup>Ornimundo, S/n, Porto, Portugal, <sup>2</sup>Bairbre O'Malley Veterinary Hospital, S/n, sn, Ireland, <sup>3</sup>Universidade de Trás-os-Montes e Alto Douro, Veterinary Sciences, Vila Real, Portugal

**Introduction:**

The guinea pig has become popular as a pet in recent decades, so it's relevant to study the most frequent diseases among which we highlight the diseases of the lower urinary tract [urolithiasis; cystitis, lower urinary tract infection (UTI)].

**Objectives:**

The aim was to analyze population characteristics, clinical presentation, diagnosis, treatment and response to treatment.

**Methods:**

This is a retrospective study and data were obtained by a search of clinical records from Bairbre O'Malley Veterinary Hospital, Ireland.

**Results:**

Records of 117 cases were analyzed, 68 females and 49 males. The mean age of the piglets was 3 years (minimum 1, maximum 7). Gender showed statistically significant association with diagnosis ( $p=0.002$ ) (males urolithiasis; females cystitis and UTI); anatomical location of urolithiasis ( $p=0.001$ ) (urethra in females, bladder in males); disease recurrence ( $p=0.025$ ) (higher in females); and with a family history of urinary diseases, ( $p<0.001$ ) (females with a higher incidence of linking to family history of disease). A statistically significant association was also observed between disease recurrence and diagnosis ( $p=0.005$ ) (animals with a presumptive diagnosis of cystitis or UTI recurred the most). The associations between hematuria and diagnosis ( $p<0.001$ ) and pain on palpation with diagnosis ( $p=0.012$ ) also showed statistical significance. The absence of these clinical signs was more frequent in animals with urolithiasis. Regarding treatment, the usage of potassium citrate was associated with a better response to treatment ( $p=0.004$ ).

**Conclusions:**

Lower urinary tract diseases are common and easily treatable in guinea pigs. However, the high rate of recurrences requires a systematized clinical approach and careful medical follow-up.

**P033 / #646**

**Topic:** *AS11 Exotics*

## **EFFICACY OF SAROLANER AGAINST PSOROPTES OVIS IN NATURALLY INFESTED RABBITS**

M. Machado, D. Borges, D. Campos, J. Fernandes  
Universidade Federal Rural do Rio de Janeiro, Departamento De Parasitologia Animal,  
Seropédica, Brazil

### **Introduction:**

The pet rabbit has become popular in Brazilian homes, increasing the need for specialized veterinary care. One of the most common disease of rabbits is the Psoroptic mange, that is caused by *Psoroptes ovis* and has a pruritus action, with the formation of scabs and lesions mainly in the pinna (otitis) of rabbits. Despite its gravity, there are a few studies with commercial products to *P. ovis* control.

### **Objectives:**

The aim of this study was to evaluate the efficacy of sarolaner for the control of *P. ovis* in naturally infested rabbits.

### **Methods:**

Twelve rabbits with psoroptic mange were divided in two groups (n=6), control group, untreated; treated group received sarolaner at a dose of 2mg/kg, administered orally, in a single dose. Samples of rabbits' pinna scabs were obtained with cotton swabs from both ears and transferred to a glass slide. Mineral oil was added and the slides were observed by optical microscopy at  $\times 10$ , magnification, in order to confirm the presence or absence of *P. ovis*. Evaluations occurred before and at +3, +7, +14, +21, +28, +35 after treatment.

### **Results:**

Rabbits belonging to the control group remained infested by *P. ovis* throughout the entire experimental period. From the +3 evaluation, only one rabbit was positive for the presence of the mite and from the day +7 to +35 treated group had 100% of efficacy against *P. ovis*.

### **Conclusions:**

Administration of a single oral dose of sarolaner was effective for the treatment of naturally *P. ovis* infestation in rabbits during a 35-day period.

**P034 / #650**

**Topic:** *AS11 Exotics*

**DEVELOPMENT, VOLUNTARY INTAKE AND PALATABILITY OF MEDICATED BAIT BLOCK CONTAINING FLUAZURON FOR GUINEA PIGS (CAVIA PORCELLUS)**

D. Borges<sup>1</sup>, Y. Cid<sup>2</sup>, M. Alves<sup>1</sup>, I. Bonfim<sup>1</sup>, I. Jesus<sup>1</sup>, F. Scott<sup>1</sup>

<sup>1</sup>Universidade Federal Rural do Rio de Janeiro, Animal Parasitology Department, Seropédica, Brazil, <sup>2</sup>Universidade Federal Rural do Rio de Janeiro, Pharmaceutical Science Department, Seropédica, Brazil

**Introduction:**

The availability of bait blocks containing fluazuron to wild rodents has been studied to control pathogens transmissible for ectoparasites to humans. Capybaras are hosts for the tick *Amblyomma sculptum* that can cause the Brazilian Spotted Fever. As capybaras and guinea pigs belong to the Caviidae family and have very similar behavior, we chose to do this preliminary study with guinea pigs.

**Objectives:**

In order to provide, in the future, feed cubes containing fluazuron for use in capybaras to control the tick *A. sculptum*, the aim of this study was to develop a bait block containing fluazuron and evaluate the voluntary intake and palatability for guinea pigs.

**Methods:**

The blocks were submitted to resistance tests and evaluations of its organoleptic properties. After the choose of the best bait block, they were offered to the animals. Twenty-four guinea pigs were divided into two groups: Placebo group, received the block without fluazuron; and treated group, received the same block but containing 5mg of fluazuron. The evaluations of voluntary intake and palatability occurred accordingly with the "Guideline on the demonstration of palatability of veterinary medicinal products".

**Results:**

The results of the chosen formulation are in accordance with the pharmacopeial acceptance criteria. The bait block is palatable i.e. it is usually taken voluntarily by guinea pigs on at least 90% of occasions in animals studied.

**Conclusions:**

The bait block containing fluazuron was considered ready to proceed to the efficacy studies, as it had good acceptance by the animals.

**P035 / #567**

**Topic:** AS12 *Feline medicine*

## **FELINE URINARY TRACT PATHOGENS IN WESTERN CANADA: PREVALENCE OF BACTERIAL SPECIES AND ANTIMICROBIAL RESISTANCE FROM 2012 TO 2018**

C. Hansen-Jones<sup>1</sup>, N. Cogger<sup>2</sup>, K. Hill<sup>2</sup>

<sup>1</sup>Macleod Trail Animal Hospital, Medical Director, Calgary, Canada, <sup>2</sup>Massey University, Veterinary Science, Palmerston North, New Zealand

### **Introduction:**

Feline lower urinary tract disease (FLUTD) is a common cause for the prescription of antimicrobials, despite the relatively low proportion of bacterial cases. Guidelines by the International Society of Companion Animal Infectious Diseases (ISCAID) advise all FLUTD treatment be directed by culture and sensitivity. There are times where client or patient factors preclude sensitivity testing, and then knowledge of local bacterial populations may help direct therapy.

### **Objectives:**

To investigate trends in the bacterial population and antimicrobial resistance in bacteria isolated from feline urine from 2012 to 2018 in Alberta and British Columbia, Canada.

### **Methods:**

Idexx Laboratories provided data for urine samples collected by cystocentesis submitted for aerobic culture and sensitivity during the study period.

### **Results:**

From the 8084 isolates, the most common bacteria were, *Escherichia coli*, *Enterococcus* species, and *Staphylococcus* species at 60.0%, 22.7% and 11.8% respectively. Over the study resistance to clindamycin increased from 9.9% to 24.6%. Bacterial isolates in the study were most likely to be susceptible to nitrofurantoin, enrofloxacin, marbofloxacin, amoxicillin with clavulanic acid, doxycycline, and amoxicillin.

### **Conclusions:**

The proportion of *Enterococcus* species isolated was higher in this study than European studies but similar to past North American papers. Increasing resistance to clindamycin may be a concern if similar patterns are found in bacteria isolated from other tissues. Based on this study and ISCAID guidelines treatment with amoxicillin with or without clavulanic acid, or doxycycline may be considered for infectious feline lower urinary tract disease in Alberta and British Columbia, while awaiting sensitivity testing.



**Topic:** *AS12 Feline medicine*

**ISOLATION OF FELINE CORONA VIRUS FROM AQUEOUS HUMOR SAMPLE OF A 9 MONTHS OLD DSH CAT WITH DRY FORM OF FELINE INFECTIOUS PERITONITIS**

H. Jahani<sup>1</sup>, S. Farzad-Mohajeri<sup>2</sup>, I. Ashrafi-Tamai<sup>3</sup>, A. Rajabi Majd<sup>1</sup>, N. Ameri<sup>4</sup>

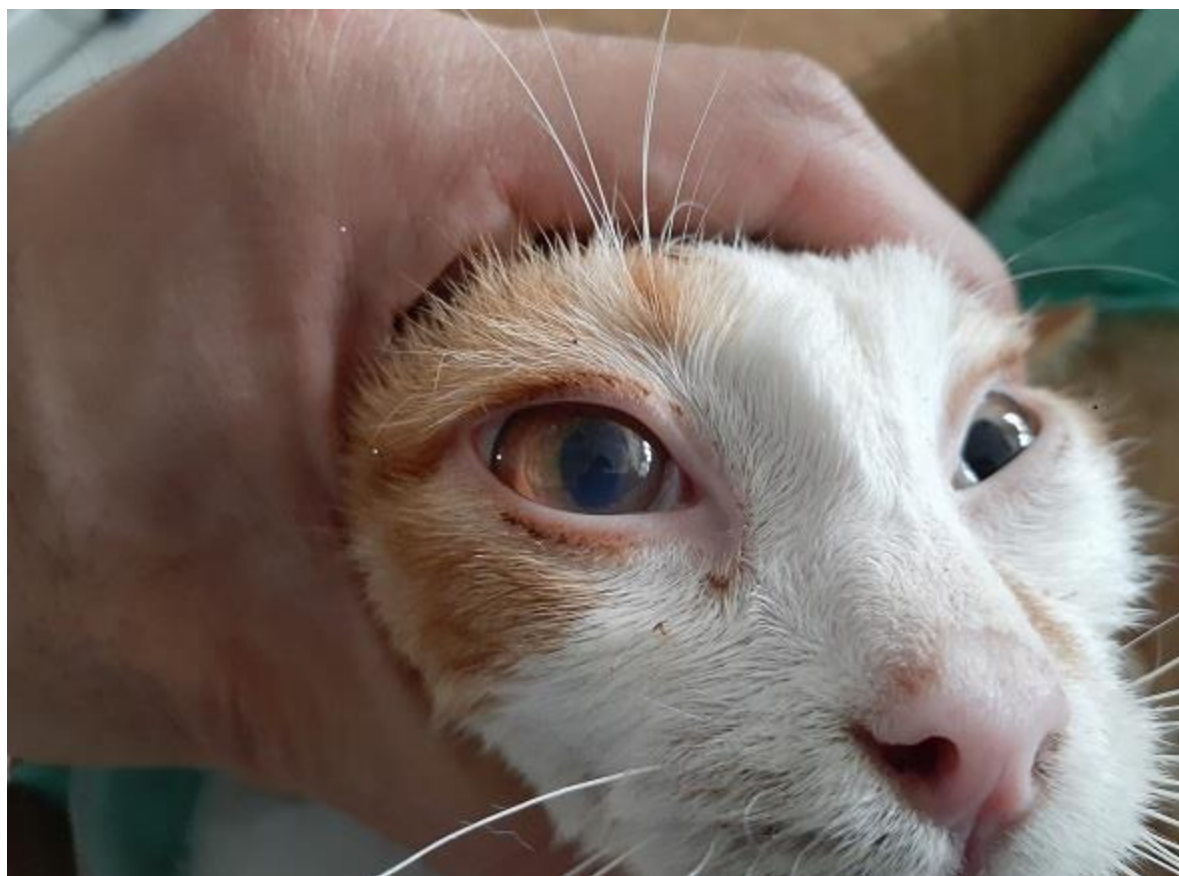<sup>1</sup>Faculty of Veterinary Medicine, University of Tehran, Tehran, Iran, Internal Medicine, Tehran, Iran, <sup>2</sup>Faculty of Veterinary Medicine, University of Tehran, Tehran, Iran, Surgery And Radiology, Tehran, Iran, <sup>3</sup>Faculty of Veterinary Medicine, University of Tehran, Tehran, Iran, Microbiology, Tehran, Iran, <sup>4</sup>Faculty of Veterinary Medicine, University of Tehran, Tehran, Iran, Surgery And Radiology, Tehran, Iran

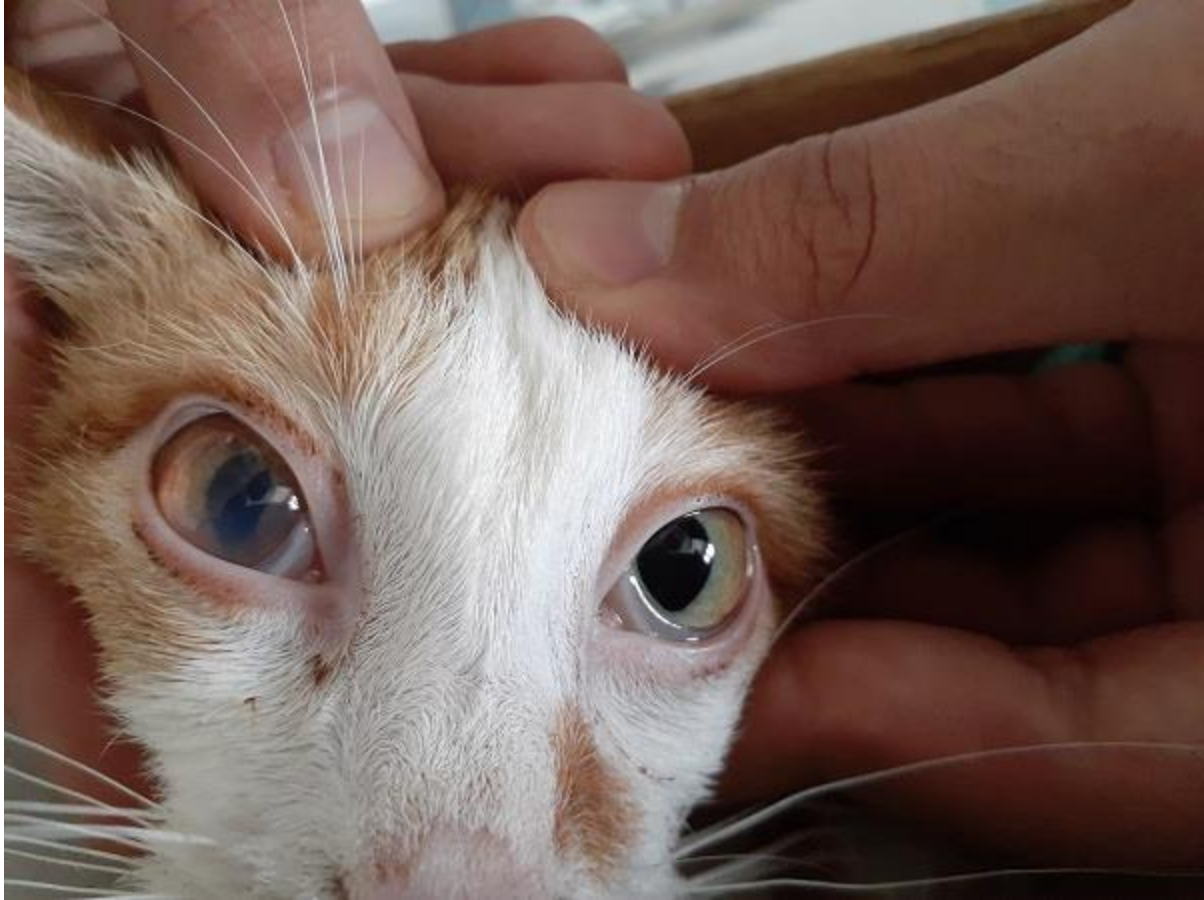**Introduction:**

Feline coronavirus(FCoV) infection is very common in cats but up to 10% of FCoV infections result in Feline Infectious Peritonitis(FIP). FIP typically manifests as a wet(effusive) form or dry(non-effusive) form. Diagnosis of FIP, especially the dry form, is challenging. The most definitive diagnosis of FIP is based on combination of characteristic histopathologic findings with presence of coronavirus by virus isolation, immunocytochemical or immunohistochemical staining, or amplification of viral RNA in effusion, other fluids like CS or aqueous humor or tissues by RT-PCR.

**Objectives:**

A 9-month-old stray DSH cat had shown clinical signs of lethargy, hyporrhexia, weight loss and progressive ataxia since adoption. The case was recumbent, had signs of UMN tetraparesis, uveitis and iritis in the right eye and a mild lymphopenia on examination day. According to history, clinical examination, neurological and ocular clinical signs, our presumptive diagnosis was Dry form of FIP which was confirmed by aqueous humor RT-PCR.



**Methods:**

Aqueocentesis was performed under general anesthesia and aseptic condition . Also blood sample was taken in heparinized tube on which RT-PCR was performed.

**Results:**

FCoV was not detected in blood RT-PCR but was detected in aqueous humor sample, emphasizing the importance of how and where to sample for RT-PCR.

**Conclusions:**

Due to the fact that in most cases of dry FIP, either neurologic or ophthalmic tissues are affected, one of the most precise methods to diagnose this infection seems to be performing RT-PCR on CSF or aqueous humor samples.

**P037 / #621**

**Topic:** AS12 *Feline medicine*

## **CANINE-ORIGIN PLATELET-RICH FIBRIN (PRF) HEMODERIVATIVE: A POTENTIAL TREATMENT FOR FELINE WOUND REGENERATION**

C. Soares<sup>1,2</sup>, I. Dias<sup>1,3</sup>, M. Pires<sup>1,2</sup>, P. Carvalho<sup>4,5</sup>

<sup>1</sup>CECAV, University Of Trás-os-montes E Alto Douro (utad), Vila Real, Portugal, <sup>2</sup>Laboratory of Histology and Anatomical Pathology, UTAD, University Of Trás-os-montes E Alto Douro (utad), Vila Real, Portugal, <sup>3</sup>ICVS/I3Bs, University Of Minho, Guimarães, Portugal, <sup>4</sup>CIVG, Veterinary Department, Vasco Da Gama Research Center, University School Vasco Da Gama - Euvg, Coimbra, Portugal, <sup>5</sup>Vetherapy, Research And Development In Biotechnology, Coimbra, Portugal

### **Introduction:**

Platelet-rich fibrin (PRF) is a novel hemoderivative advanced for the treatment of human skin wounds. As low blood-volume donors, autologous PRF-therapy is limited in felines, and xenogenic PRFs may constitute a suitable option for feline wound regeneration, as topical xenogenic platelet-therapies have been reported.

### **Objectives:**

We aimed to evaluate the therapeutic safety and effectiveness of canine-origin PRFs for the treatment of feline skin wounds, and quantification of bioactive healing proteins from canine-PRFs.

### **Methods:**

This case study considered three compromised cats, presenting naturally occurring wounds (Ethics approval 60-CE-2020), all infected. Two cats were anemic, with concomitant co-morbidities: cases 2 and 3 were infected with feline immunodeficiency virus and case 3 was also tested positive for *Bartonella* sp.).

Each treatment consisted in the application of PRF, derived from screened canine donors, into the wound, followed by a closed bandage. No antiseptics were applied.

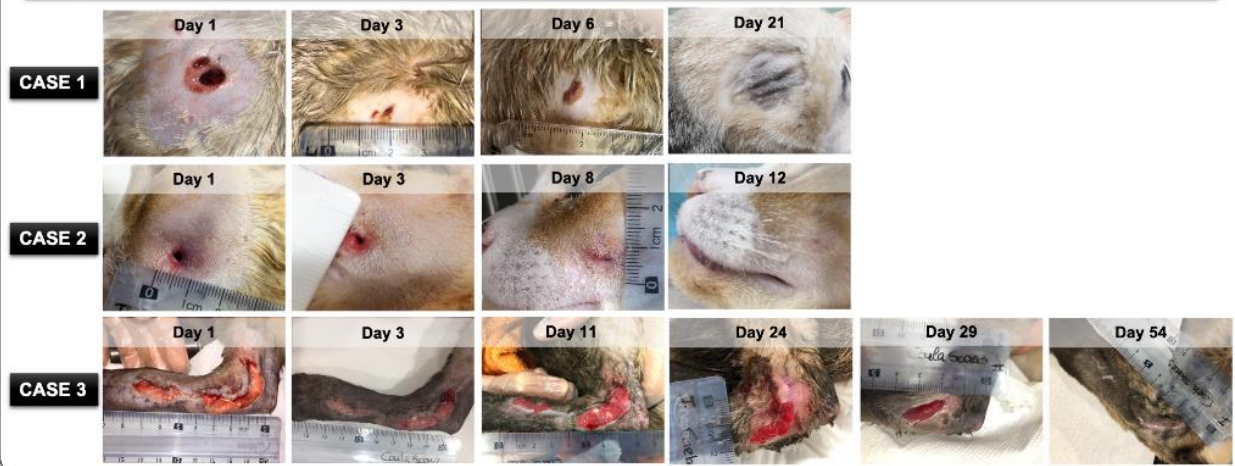Four additional canine-PRFs were submitted to protein quantification, by Enzyme-Linked Immunosorbent Assay.

The wound area was assessed using ImageJ® and statistical analysis was conducted using GraphPad®.

### **Results:**

At day-1 wound area ranged from 2.26- 7.01 cm<sup>2</sup>, recording an 87.23% median reduction after the second PRF-treatment. No rejection/necrosis/infection were recorded (Fig1).

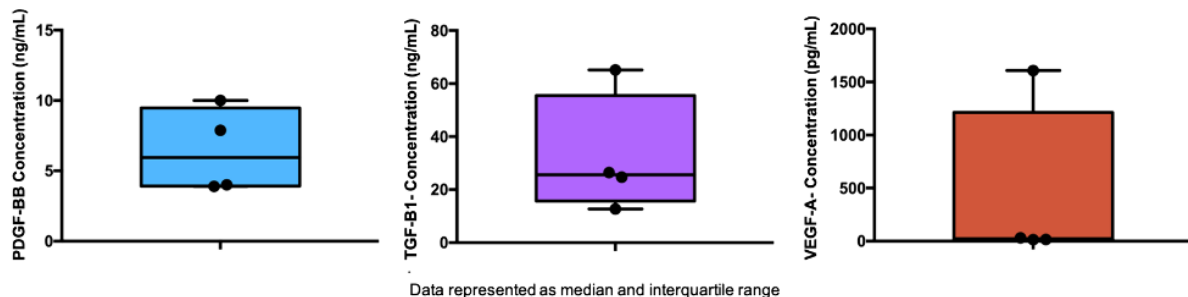
**Fig 1. MACROSCOPIC EVALUATION OF CANINE-ORIGIN PRF-THERAPY ON FELINE SKIN WOUNDS**



Canine-origin PRF-therapy did not reveal any adverse effects.

Platelet-derived growth factor-BB (PDGF-BB), transforming growth factor beta-1 (TGF- $\beta$ 1) and vascular endothelial growth factor-A (VEGF-A) were present in canine-PRFs (Fig2).

**Fig 2. QUANTIFICATION OF ACTIVE PROTEINS RELEASED FROM CANINE-PRFs (n=4)**



## Conclusions:

Canine-PRFs treated complex wounds in compromised cats, inducing significant granulation tissue in lesions with tissue deficit, resulting in vestigial scars, without complications.

PRFs may unveil antimicrobial activity and release active healing proteins.

**P038 / #622**

**Topic:** *AS12 Feline medicine*

**RANDOMIZED, PLACEBO-CONTROLLED, 28-DAY SAFETY EVALUATION OF REPEATED ORAL CANNABIDIOL ADMINISTRATION IN HEALTHY CATS**

J. Kulpa, D. Vaughn

Canopy Growth Corporation, Human And Animal Research Program, Evergreen, United States of America

**Introduction:**

There is increasing interest in the therapeutic potential of cannabidiol (CBD) in veterinary species. Few studies have explored safety of CBD, particularly as a highly purified molecular entity, in cats.

**Objectives:**

To determine the safety and tolerability of an orally delivered CBD formulation in cats.

**Methods:**

In this randomized study, twenty healthy cats were assigned to receive sunflower (SF) oil placebo, or 1, 2, 4 or 12 mg/kg CBD isolate in SF oil. Test articles were administered once daily via oral syringe for 28 days. Safety and tolerability were determined from clinical observations, veterinary examinations, complete blood count and clinical chemistry. Adverse events (AEs) were rated as mild, moderate, or severe/medically significant and classified by body system.

**Results:**

Repeated CBD administration was well tolerated by cats, with no clinically important changes in measured safety outcomes. Of the 144 mild AEs observed across this study, 55% were gastrointestinal events, followed by ocular (15%), cardiovascular (11%), constitutional signs (11%) and neurological (9%) events. Relative to placebo, CBD administration at 4 and 12 mg/kg resulted in more gastrointestinal AEs (mainly hypersalivation). All AEs were transient and self-limiting, resolving without medical intervention. Elevation of alanine aminotransferase (ALT) was seen in animals treated with 4 mg/kg (n=1) and 12 mg/kg (n=3) CBD, beginning one to three weeks after dosing initiation. There were no clinical signs of liver toxicity.

**Conclusions:**

Cats tolerated repeat dosing with orally delivered CBD well. These findings provide support for continuing research on the safety and potential therapeutic uses of orally delivered CBD in felines.

**P039 / #568**

**Topic:** *AS13 Gastroenterology and hepatology*

## **SEGMENTAL APLASIA OF THE CAUDAL VENA CAVA AS INCIDENTAL FINDING IN ONE DOG**

I. Pereira<sup>1,2,3</sup>, D. Méndez<sup>1</sup>, C. Nunes<sup>4</sup>, L. Saldías<sup>3</sup>, A. Valdés<sup>1</sup>, D. Sáez<sup>4</sup>, D. Pincheira<sup>3</sup>

<sup>1</sup>Red Atención Veterinaria Universidad de Chile, Gastroenterology, Santiago, Chile, <sup>2</sup>Vetpoint, Gastroenterology, Santiago, Chile, <sup>3</sup>Hospital Medivet, Internal Medicine, Santiago, Chile, <sup>4</sup>Vetpoint, Imagenology, Santiago, Chile

### **Introduction:**

Segmental caudal vena cava aplasia (SCVCA), is an uncommon vascular congenital anomaly in dogs, most of the time is not associated with clinical signs, usually observed as an incidental finding during imaging studies, laparotomy or anatomic dissection.

A 2-year-old, mixed-breed dog went to a veterinary medical consultation for castration. In the clinical examination, unilateral cryptorchidism was found, and then referred for an abdominal ultrasound. The ultrasound revealed a retained testicle in abdominal cavity and suspected portosystemic vascular anomal, then a Computed tomography (CT) was performed, revealing (SCVCA)

### **Objectives:**

Describe imagenologic findings of the (SCVCA)

### **Methods:**

The study was carried on a 16-channel helical Philips Brilliance tomography machine, in simple and contrasted elimination phase

### **Results:**

Caudal vena cava of normal course was evidenced from its formation in the iliac veins to the left renal vein, where a shift to the right was observed, coming into contact with the ventral aspect of the right kidney and then moving dorsally and at the level of T13 anastomosing to the azygous vein, the which was observed markedly dilated. No vena cava image was observed at its entrance to the liver. Hepatic veins were observed converging in the groove for the vena cava giving rise to the corresponding segment of the caudal vena cava which in turn entered through the foramen for the vena cava into the thoracic cavity, reaching the right atrium normally

### **Conclusions:**

As concordant with the literature, our dog presented (SCVCA) as incidental finding. Ultrasound may suggest Portosystemic anomalies, but CT is mandatory for final diagnosis.

**P040 / #616**

**Topic:** *AS14 Hereditary diseases*

**PREVALENCE AND RISK FACTORS FOR MYOSIN-BINDING PROTEIN C3 (MYBPC3) A31P MUTATION IN MAINE COON CATS WITH HYPERTROPHIC CARDIOMYOPATHY IN THAILAND**

P. Sukumolanan<sup>1</sup>, S. Petchdee<sup>2</sup>

<sup>1</sup>Kasetsart University, Veterinary Clinical Studies Program, Faculty Of Veterinary Medicine, Nakorn Pathom, Thailand, <sup>2</sup>Kasetsart University, Large Animal And Wildlife Clinical Sciences, Faculty Of Veterinary Medicine, Nakorn Prathom, Thailand

**Introduction:**

The missense mutation of myosin-binding protein C3 (MYBPC3) A31P, sarcomeric protein in the myocardium, is associated with hypertrophic cardiomyopathy (HCM) in Maine Coon cats. Moreover, HCM is found at a young age and demonstrated more severe disease progression in cats affected MYBPC3 A31P mutation.

**Objectives:**

This study aims to determine the prevalence of MYBPC3 A31P mutation in Maine Coon cats in Thailand and to evaluate the risk factor of HCM affected Maine Coon cats.

**Methods:**

Forty-seven Maine Coon cats were recruited into this study according to inclusion and exclusion criteria. Signalments, body weight, and complete physical examination were examined. Echocardiography was performed to characterized the HCM phenotype. A blood sample was genotyped for MYBPC3 A31P polymorphism. The prevalence of MYBPC3 A31P mutation and correlation among clinical parameters and HCM were calculated.

**Results:**

In this study, we found that the prevalence of MYBPC3 A31P mutation in Maine Coon cats is 17.03% (8/47), composing of 2.13% (1/47) homozygous mutation and 14.90% (7/47) heterozygous mutation. In addition, left ventricular hypertrophy in Maine Coon cats was positively correlated with body weight ( $r = 0.46$ ,  $p = 0.013$ ). However, echocardiographic results showed no significant difference among group.

**Conclusions:**

The prevalence of MYBPC3 A31P mutation was 17.03% in the Thailand Maine Coon cat population. The elevated body weight has increased the risk of HCM. Therefore, decreasing of MYBPC3 A31P mutation may decline the familial HCM in Maine Coon cats.



**Topic:** *AS15 Infectious and emerging diseases*

## **ZOONOTIC BABESIOSIS: A REVIEW ON EVIDENCE BASED ZOONOTIC THREATS AND KNOWLEDGE GAPS**

S. Hussain<sup>1</sup>, A. Hussain<sup>2</sup>, M. Aziz<sup>3</sup>, B. Song<sup>4</sup>, J. Zeb<sup>5</sup>, D. George<sup>6</sup>, J. Li<sup>1</sup>, O. Sparagano<sup>1</sup>

<sup>1</sup>City University of Hong Kong, Infectious Diseases And Public Health, Kowloon, Hong Kong PRC, <sup>2</sup>University of Veterinary and Animal Sciences, Lahore, Epidemiology And Public Health, Lahore, Pakistan, <sup>3</sup>University of Veterinary and Animal Sciences, Clinical Medicine, Lahore, Pakistan, <sup>4</sup>West Normal University China, College Of Life Science, Sichuan, China, <sup>5</sup>Abdul Wali Khan University, Department Of Zoology, Mardan, Pakistan, <sup>6</sup>Newcastle University, School Of Natural And Environmental Sciences, New Castle, United Kingdom

### **Introduction:**

Babesiosis is an emerging zoonotic disease caused by a tick-borne intraerythrocytic protozoan of the *Babesia* spp. Group, which becomes an increasing public-health threat. The main vector responsible for the transmission of babesiosis is the *Ixodes scapularis* tick, which is of prime zoonotic importance as it also plays role in spreading Lyme Disease and Anaplasmosis. Drastic environmental changes have played a pivotal role in indigenous ticks to pick up imported pathogens and are expected to widen the boundaries of tick-borne diseases including zoonotic babesiosis.

### **Objectives:**

The study was designed to assess the threat through finding research gaps where more work is needed to mitigate the effects of zoonotic babesiosis.

### **Methods:**

Three databases (i.e., Google Scholar, Web of Science and PubMed) were used to search for published studies available online in English language by using relevant keywords.

### **Results:**

After reviewing hundreds of published articles about zoonotic babesiosis, we found none related to modeling about effect of climate change on *Babesia* species. Many *Babesia* species infect animals, but *B. microti*, *Babesia divergens*, *Babesia duncani*, and *Babesia venatorum* are of major zoonotic threat. Literature showed the incidence of zoonotic babesiosis has increased approximately 3-fold.

### **Conclusions:**

This review paper suggested the gaps including lack of research regarding economic losses due to babesiosis, surveillance of pathogen in animals and vectors, tick resistance and modelling regarding the effect of climate change on vectors' geographic distribution. These gaps

demand to pay attention to future threats associated with zoonotic babesiosis which can only be minimized by proper policies, and key strategic developments.

**P042 / #530**

**Topic:** *AS15 Infectious and emerging diseases*

## **PREVALENCE OF FELINE CORONAVIRUS IN CATS FROM ANIMAL SHELTERS IN LATVIA**

G. Mūrniece, K. Kovaļenko

Latvia University of Life Sciences and Technologies, Faculty Of Veterinary Medicine, Institute Of Food And Environmental Hygiene, Jelgava, Latvia

### **Introduction:**

Feline coronavirus (FCoV) is highly contagious, and it is ubiquitous in multicat environments. Up to 10% of FCoV infections lead to highly fatal feline infectious peritonitis (FIP). FIP is one of the most significant infectious diseases of cats. FCoV is prevalent worldwide; however, information on prevalence in local domestic cat (*Felis catus*) population is scarce.

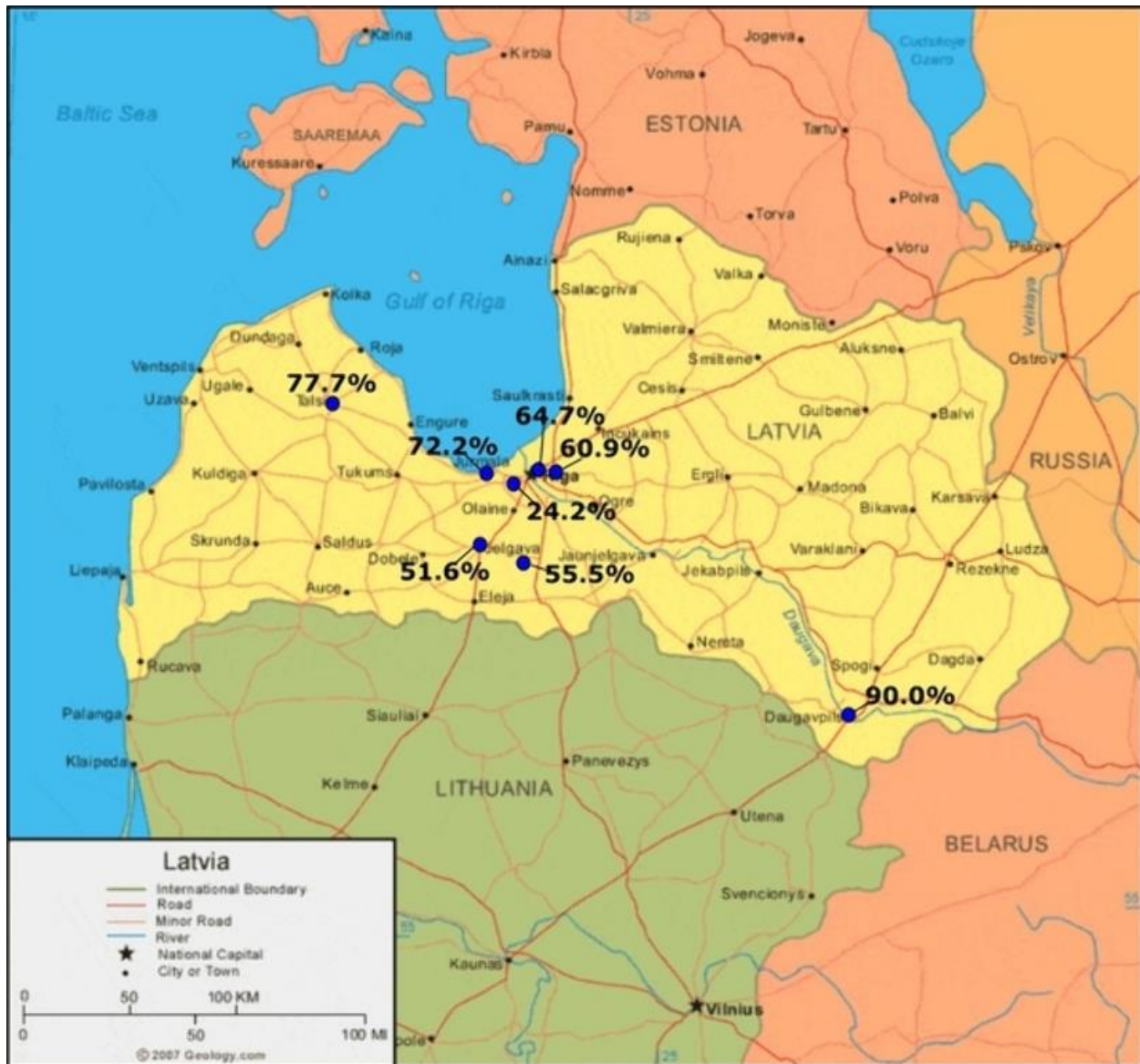### **Objectives:**

The aim of this study was to screen the presence of FCoV in cats from animal shelters in Latvia.

### **Methods:**

This cross-sectional study included 218 cats from eight animal shelters in Latvia. From each cat two polyester-tipped swabs (oropharyngeal and rectal) were collected. Swabs were analysed for FCoV RNA by reverse transcriptase-polymerase chain reaction (RT-PCR).

### **Results:**



FCoV was present in all shelters, with prevalence ranging from 24,4% to 90,0%. The overall prevalence across all shelters was 56,4%. FCoV RT-PCR positivity in oropharyngeal and rectal swabs was 8,7% (19/218) and 56,4% (123/218), respectively.

### Conclusions:

Substantial proportion (56,4%) of examined cats were shedding FCoV. This study illustrates the prevalence of FCoV in animal shelters in Latvia. Based on this we can be aware of FCoV topicality and derive recommendations to limit the transmission.

**Topic:** *AS15 Infectious and emerging diseases*

## **SEROPREVALENCE OF DIROFILARIA IMMITIS IN CATS FROM SPAIN**

S.N. García Rodríguez<sup>1</sup>, R. Morchón García<sup>2</sup>, J.I. Matos Rivero<sup>1</sup>, N. Costa Rodríguez<sup>1</sup>, E. Carretón Gómez<sup>1</sup>, J.A. Montoya Alonso<sup>1</sup>

<sup>1</sup>University of Las Palmas of Gran Canaria, Internal Medicine, Faculty Of Veterinary Medicine, Research Institute Of Biomedical And Health Sciences (iuibs), Las Palmas de Gran Canaria, Spain, <sup>2</sup>University of Salamanca, Laboratory Of Parasitology, Faculty Of Pharmacy, Salamanca, Spain

### **Introduction:**

*Dirofilaria immitis* is a parasitic nematode responsible of cardiopulmonary dirofilariosis which is endemic in Spain, being reported in dog from almost all the country; furthermore, feline infections are being diagnosed with increasing frequency in areas where the disease is endemic in dogs. Cats generally tolerate the infection being asymptomatic or showing imperceptible/transient clinical signs; sometimes sudden death is the only symptom.

### **Objectives:**

This study establishes the first epidemiological report of feline seroprevalence of *D. immitis* in all the Spanish territory.

### **Methods:**

Samples of 5199 client-owned cats were collected between September 2020 and July 2021 from 103 veterinary centers located in all the autonomous communities (17) and autonomous cities (2) from Spain. Sera were analyzed by serological techniques for anti-*D. immitis* and anti-Wolbachia antibody detection. Results were analyzed by using SPSS Base 25.0 software.

### **Results:**

A global seroprevalence of 9.65% was reported. The highest seroprevalences were found in the Balearic and Canary Islands (18.18-19.10%) and ranges from 7.14% to 11.03% were shown in the Mediterranean coast and Southern communities. The lower seroprevalences were found in the Northern communities (2.94-5.40%). Positive cats were found in the entire studied territory.

### **Conclusions:**

The feline population is highly exposed to dirofilariosis. Based on the results, it is advisable to recommend annual prophylactic measures against *D. immitis* in cats in Spain, as well as to raise awareness of the need to prevent dirofilariosis in this species, both among owners and veterinarians.

This research was supported by MERCK SHARP & DOHME ANIMAL HEALTH, S.L.

**P044 / #556**

**Topic:** *AS15 Infectious and emerging diseases*

## **PERSISTENCE OF CANINE PARVOVIRUS MODIFIED-LIVE VIRUS IN CANINE TISSUES**

G. Schirò<sup>1</sup>, F. Mira<sup>1</sup>, N. Decaro<sup>2</sup>, C. Desario<sup>2</sup>, G. Chiaramonte<sup>1</sup>, S. Di Bella<sup>1</sup>, V. Cannella<sup>1</sup>, G. Purpari<sup>1</sup>, G. Ventriglia<sup>2</sup>, F. Gucciardi<sup>1</sup>, D. Vicari<sup>3</sup>, V. Randazzo<sup>3</sup>, A. Guercio<sup>1</sup>

<sup>1</sup>Istituto Zooprofilattico Sperimentale della Sicilia "A. Mirri", Area Diagnostica Virologica, Palermo, Italy, <sup>2</sup>University of Bari, Department Of Veterinary Medicine, Valenzano, Italy, <sup>3</sup>Istituto Zooprofilattico Sperimentale della Sicilia "A. Mirri", Area Territoriale Palermo, Palermo, Italy

### **Introduction:**

Canine parvovirus (CPV) modified-live virus vaccines can replicate in lymphopoietic tissues and intestinal mucosa after their administration, being shed through canine faeces. Detection of vaccine strains has been reported in the bloodstream and faeces, potentially interfering with molecular diagnostic tests.

### **Objectives:**

The persistence of these strains in canine tissues has not yet been described. With this aim, canine tissues were tested during a molecular survey to screen for the presence of canine enteric viruses.

### **Methods:**

Tissue samples from 159 dead dogs were tested by a conventional PCR assay. Positive samples and five commercial vaccines were subject to sequence analysis. Vaccinal strains were further detected and titrated by using a set of real-time PCR assays using minor-groove binder (MGB) probes.

### **Results:**

Seventy dogs (44%) tested positive for CPV. Strains from 65 dogs were characterised as field variants. The presence of CPV-2 sequences of vaccine origin was observed in spleen, intestine, and mesenteric lymph nodes of five young dogs. Vaccinal strains were detected from 12 to 21 days after the last vaccine administration. Viral loads were comprised between  $6.3 \times 10^3$  and  $9.95 \times 10^4$  DNA copies/10 µl of template.

### **Conclusions:**

This study confirms that CPV vaccinal strains can be detected in canine tissues after vaccination, so that post-mortem diagnosis of CPV infection needs further molecular analyses to assess the viral type (vaccine or field strains). The present study updates the current information on the persistence of CPV vaccines in the organism and their possible interference with molecular assays.

**Topic:** *AS15 Infectious and emerging diseases*

**EFFECT OF DOMPERIDONE (LEISGUARD®) ON ANTIBODY TITERS, INFLAMMATORY MARKERS AND CREATININE IN LEISHMANIOTIC DOGS WITH CKD**

M.A. Cavallera<sup>1</sup>, F. Gernone<sup>1</sup>, A. Uva<sup>1</sup>, P. D'Ippolito<sup>2</sup>, X. Roura<sup>3</sup>, S. Paltrinieri<sup>4</sup>, A. Zatelli<sup>1</sup>

<sup>1</sup>University of Bari, Department Of Veterinary Medicine, Valenzano, Italy, <sup>2</sup>Veterinary diagnostic Lab ACV Triggiano, Lab Acv Triggiano, triggiano, Italy, <sup>3</sup>Hospital Clínic Veterinari, Universitat Autònoma De Barcelona, Bellaterra, Spain, <sup>4</sup>University of Milan, Department Of Veterinary Medicine, Lodi, Italy

**Introduction:**

Immunotherapeutic treatments, as domperidone, have shown to be promising against canine leishmaniosis reestablishing the dog's immunity and, therefore, promoting parasite reduction and improving clinical signs. Furthermore, domperidone is a peripheral specific dopamine 2 (DA<sub>2</sub>) receptor antagonist, and evidence suggested that in dogs intrarenal DA<sub>2</sub> receptor plays a role in the control of renal function.

**Objectives:**

This pilot study (therapeutic, prospective and non-controlled) aims to evaluate the effect of domperidone on serum antibody titers for *Leishmania infantum*, globulins, gamma globulins and acute-phase proteins (c-reactive protein [CRP]), big endothelin-1 [big ET-1] as well as on serum creatinine (SC) and proteinuria in leishmaniotic dogs affected by chronic kidney disease (CKD).

**Methods:**

Dogs were recruited if 'exposed' or 'infected' to *L. infantum*, affected by CKD (IRIS stage 1 proteinuric or IRIS stage 2-3a [SC<3.5mg/dL] proteinuric nor non-proteinuric). After inclusion, an oral suspension of domperidone was administered and dogs followed-up at 30, 60, 90 and 180 days.

**Results:**

Dogs (n=9) showed a statistically significant reduction of SC (P = 0.028), but not of urine protein creatinine ratio (P > 0.05). All dogs had a significant reduction of antibody titers for *L. infantum* (P = 0.008), globulins (P = 0.011) and gamma globulins (P = 0.006) during the study period. Furthermore, a statistical significance reduction of CRP (P = 0.001) but not of big ET-1 (P > 0.05) has been described.

**Conclusions:**

This study provides preliminary results on the ability of domperidone in improving SC, in reducing anti-*L. infantum* antibody titers, globulins, gamma globulins and CRP in CKD leishmaniotic dogs.

**Topic:** *AS15 Infectious and emerging diseases*

## **EFFECTIVENESS OF TINIDAZOLE AGAINST GIARDIA INFECTION IN DOGS IN SHELTER CONDITION.**

K. Tanno<sup>1</sup>, A. Umematsu<sup>2</sup>, M. Morisaki<sup>3</sup>

<sup>1</sup>Institution of Rescue Animal Medicine, Pet Satooya Clinic, saitama, Japan, <sup>2</sup>Umematsu animal hospital, Main Clinic, saitama, Japan, <sup>3</sup>Faculty of Veterinary Science, Nippon Veterinary and Life Science University, Resident Of Veterinary Medicine, tokyo, Japan

### **Introduction:**

In a shelter, it is so crucial to control various infectious disease. Especially, they have to accept many animals constantly, so it is important to treat and be cured as soon as possible. Tinidazole(TND) has good clinical anti-Giardiasis activity in human, but there are few reports evaluating the efficacy in veterinary region.

### **Objectives:**

Evaluating the usefulness of TND for Giardiasis was performed in a shelter located in Saitama, Japan.

### **Methods:**

Fourty dogs, naturally infected with Giardia were divided into four groups (n=10), which are treated with TND (45 mg/kg orally (PO) once per day, 3 days), Metronidazole (MTN) (35 mg/kg orally (PO) twice per day, 14 days), and a commercially available regimen that contained a combination of pyrantel, praziquantel, and febantel (FEB) (label dose orally (PO) once per day, 3 days). Additionally, an untreated control group was established. Fecal Giardia cyst examination was performed on day -1, 0, 5, 7, 14, and 28.

### **Results:**

All of groups showed the Giardia cyst counts reduction, however, FEB group had a higher risk of recurrence infection. In contrast to that, TND and MND groups elicited fewer recurrence rate. There are no adverse effects to dogs in all groups by administration.

### **Conclusions:**

Based on these results, the protocol administering TND as a first choice was acceptable to treat Giardiasis for its efficacy. Moreover, the implementation of a single dose is an important advantage of TND, which helps workload reduction in shelters and kennels, where taking care of large number of animals with small number of personnel.



**Topic:** *AS15 Infectious and emerging diseases*

## **SERUM AMYLOID A IN DIFFERENT STAGES OF CANINE LEISHMANIOSIS**

L. Franco Martínez<sup>1</sup>, F. Ferrández<sup>2</sup>, A. Ortín-Bustillo<sup>2</sup>, L. Pardo-Marín<sup>2</sup>, A. Tvarijonaviciute<sup>1</sup>, J. Cerón<sup>2</sup>, S. Martínez-Subiela<sup>1</sup>

<sup>1</sup>Interdisciplinary Laboratory of Clinical Analysis, Interlab-UMU, Regional Campus of International Excellence 'Campus Mare Nostrum', University of Murcia, Animal Medicine And Surgery, Murcia, Spain, <sup>2</sup>Interdisciplinary Laboratory of Clinical Analysis, Interlab-UMU, Regional Campus of International Excellence 'Campus Mare Nostrum', University of Murcia, Animal Medicine And Surgery, Murcia, Spain

### **Introduction:**

Canine leishmaniosis (CanL) diagnosis is complex due to its broad clinical spectrum (from subclinical to fatal illness) and the range of clinicopathological abnormalities that can be observed. Acute-phase proteins (APP) are biomarkers that modulate their concentration in serum shortly after inflammatory stimulus. APP have been proposed as useful markers for CanL clinical classification<sup>1</sup> and treatment monitoring<sup>2</sup>. In dogs, serum amyloid A (SAA) is a major APP, rising its serum concentration >10-fold during inflammation.

### **Objectives:**

To measure SAA in animals in different stages of CanL.

### **Methods:**

SAA was measured in n=70 canine surplus serum samples from client-owned dogs naturally infected with *L. infantum* using a validated turbidimetric assay (VET-SAA, Eiken Chemical Co., Japan). Animals were divided into three groups according to the reported classification of canine leishmaniosis based on APPs<sup>1</sup>: G1 (no clinical signs or APP changes), G2 (APP changes without the presence of other clinical signs) and G3 (clinical signs and APP changes with (G3b) and without (G3a) immune-mediated component). CRP was also measured for comparative purposes.

### **Results:**

SAA levels in G3a (median 1.9mg/L) and G3b (5.5mg/L) were significantly higher than G1 (1.1mg/L) and G2 (1.4mg/L), which may reflect the increased inflammatory status presented in animals with clinical signs of CanL. G3a and G3b did not differ significantly. Strong positive correlation between CRP and SAA ( $r^2=0.75$ ,  $p<0.001$ ) was found.

### **Conclusions:**

SAA increases in cases of canine leishmaniosis with active infection, although it did not show differences depending on the severity of the cases and is highly correlated with CRP.

**P048 / #523**

**Topic:** *AS16 Internal medicine (other)*

**CORRELATION BETWEEN SERUM N-TERMINAL PRO-B-TYPE NATRIURETIC PEPTIDE AND ECHOCARDIOGRAPHY PARAMETERS IN CANINE MYXOMATOUS MITRAL VALVE DISEASE.**

Z.P. Leong<sup>1,2,3</sup>

<sup>1</sup>Leong VetCardio Services, -, Kuala Lumpur, Malaysia, <sup>2</sup>Lee Veterinary Clinic, Kuchai Lama, Kuala Lumpur, Malaysia, <sup>3</sup>Segar Veterinary Hospital, -, Kuala Lumpur, Malaysia

**Introduction:**

The ACVIM staging of canine myxomatous mitral valve disease (MMVD) requires echocardiography but it is readily unavailable in the practice. Serum N-terminal pro-b-type natriuretic peptide (NT-proBNP) level can be easily quantified in-house. However, the relationship between this biomarker and the echocardiographic parameters remains uncertain in dogs with MMVD.

**Objectives:**

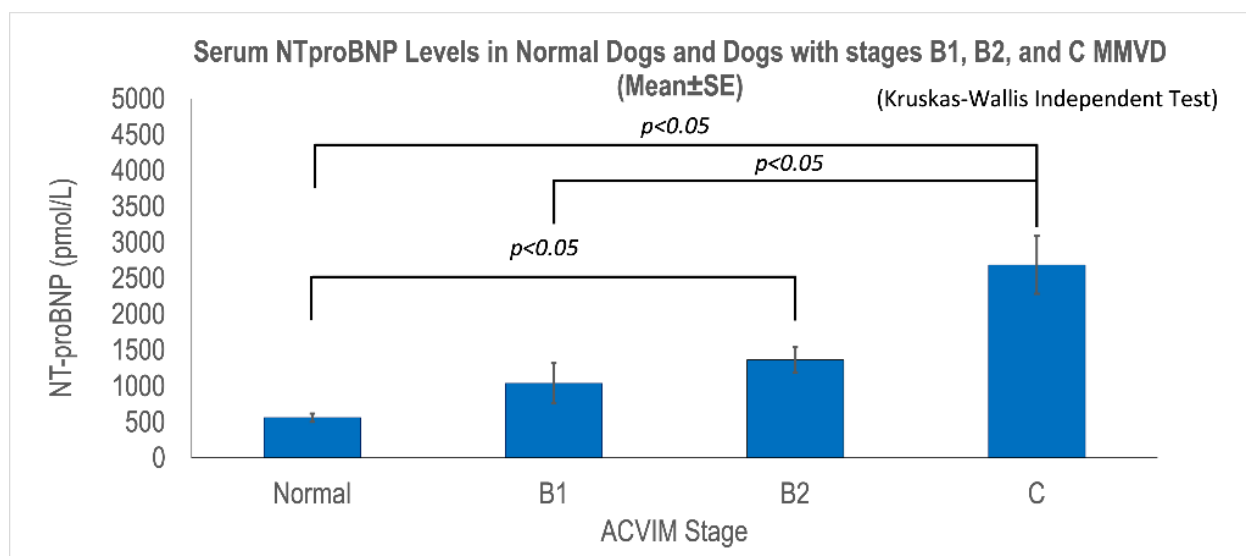
The study evaluated correlation between serum NT-proBNP levels that were measured in-house and echocardiographic parameters in dogs with MMVD, and investigated the use of serum NT-proBNP in sub-staging the MMVD.

**Methods:**

Client-owned dogs were recruited. Physical examination and blood pressure measurement were performed. Serum NT-proBNP level was measured using a Vcheck analyzer. Sub-staging of MMVD (normal, B1, B2, and C) was done using echocardiography. Inter-group differences and correlation between the NT-proBNP level and the echocardiographic indices were determined.

**Results:**

Three normal dogs and 10 MMVD dogs (B1: n=3; B2: n=3; C: n=4) were recruited. The serum NT-proBNP levels increased in accordance to the MMVD severity (normal: 559±59; B1: 1038±280; B2: 1364±177; and C: 2687±402 pmol/L) (Graph). However, the levels in the asymptomatic B1 and B2 groups, and the B2 and C groups did not differ significantly.



Further, the NT-proBNP level achieved significant correlation with  $E/E'_{\text{lateral}}$ , left atrium to aorta ratio,  $E/E'_{\text{average}}$ , transmitral E wave velocity, normalized left ventricular dimension,  $E/E'_{\text{septal}}$ , and transmitral E/A ratio (Table).

Echocardiographic Parameters	R value	P value
Transmitral E wave velocity to lateral mitral annulus velocity ( $E/E'_{\text{lateral}}$ )	0.735	0.001
Left atrium to aorta (LA:Ao) ratio	0.729	0.001
Transmitral E wave velocity to average of lateral and septal mitral annulus velocities ( $E/E'_{\text{average}}$ )	0.685	0.002
Transmitral E wave velocity (E)	0.626	0.005
Transmitral E wave velocity to septal mitral annulus velocity ( $E/E'_{\text{septal}}$ )	0.579	0.012
Normalized left ventricular end-diastolic dimension (LVDDN)	0.599	0.009
Transmitral E to A wave velocity (E/A) ratio	0.523	0.026
Transmitral E wave velocity to isovolumetric relaxation time (E/IVRT) ratio	0.479	0.052
Normalized left ventricular end-systolic dimension (LVSDN)	0.439	0.068
Pre-ejection time /left ventricular ejection time (PEP/LVET)	0.409	0.092
Diastolic blood pressure (DBP)	0.372	0.129
Mean arterial pressure (MAP)	0.356	0.147
Tricuspid annular plane systolic excursion (TAPSE)	0.157	0.533
Fractional shortening (FS)	0.099	0.696
Heart rate (HR)	0.062	0.808
Ejection fraction (EF)	0.014	0.957
Systolic blood pressure (SBP)	-0.121	0.631
Isovolumetric relaxation time (IVRT)	-0.150	0.565
Left Tei index	-0.172	0.525
Transmitral A wave velocity (A)	-0.179	0.478
Deceleration time (DecT) of transmitral E wave	-0.197	0.433

(Data analyzed using Spearman's rho at significance level of  $P < 0.05$ )

## Conclusions:

An increased serum NT-proBNP level indicates severity of the MMVD due to elevated left atrioventricular wall stress. However, when echocardiography is not available, using the biomarker as a sole means to sub-stage the MMVD is not recommended.

**P049 / #584**

**Topic:** *AS16 Internal medicine (other)*

## **SNAKE ENVENOMATION IN PET DOGS PRESENTED TO A REFERRAL VETERINARY HOSPITAL IN CENTRAL PENINSULA MALAYSIA FROM 2015 TO 2019**

G.T. Selvarajah, N.A. Ahmad Annuar, S. Shitambaram, T.R.P. Tengku Azizan, A.J. Simon  
University Putra Malaysia, Department Of Veterinary Clinical Studies, Faculty Of Veterinary  
Medicine, Serdang, Malaysia

### **Introduction:**

Malaysia, with a tropical climate is a home for diverse species of snakes and incidences of snake envenomation have been frequently reported among children and people, but thus far no reports in dogs.

### **Objectives:**

The aim of this study was to describe the characteristics of snake envenomation in pet dogs; the risk factors, clinical management and outcome.

### **Methods:**

Medical records of dogs presented to a referral veterinary centre for snake envenomation cases in central peninsula Malaysia (Selangor) were retrospectively reviewed. Signalment, time of incident, clinical signs, location, site of snakebite, duration of hospitalization, treatment given and clinical outcomes were recorded.

### **Results:**

This is the first study to report on snake envenomation in dogs from central Malaysia where a total of 93 cases were reported in 5 years duration from 2015 to 2019. Three of the dogs were bitten twice. Median age of the dogs was 6 years and predominantly among local dogs. The most common snakebite site was the head region (76.0%), followed by forelimbs (12.0%) and other sites. Only 10.6% (n=17) of the dogs were presented with bite marks. Median duration for hospitalization was 2 days. Up to 69% (n=20) of the snake envenomation incident took place at night. Out of the 93 cases, 72.0% (n=67) of the dogs received antivenom in which 52 dogs recovered, 11 lost to follow up and 4 resulted in fatality.

### **Conclusions:**

Dogs treated with antivenom resulted in good clinical outcome ( $p= 0.001$ ). Majority of the cases were managed with antivenom where case fatality was recorded lower.

**P050 / #593**

**Topic:** AS16 Internal medicine (other)

## **SERUM AMYLOID A PROTEIN AS A MARKER OF INFLAMMATION IN CATS WITH AELUROSTRONGYLUS ABSTRUSUS**

N. Costa-Rodríguez, S.N. García Rodríguez, J.I. Matos Rivero, J.A. Montoya Alonso, E. Carretón Gómez

University of Las Palmas of Gran Canaria, Internal Medicine, Faculty Of Veterinary Medicine, Research Institute Of Biomedical And Health Sciences (iuibs), Las Palmas de Gran Canaria, Spain

### **Introduction:**

Cardiopulmonary nematodes are emerging parasites in the feline species in Europe. Aelurostrongylosis (*Aelurostrongylus abstrusus*) is characterized by inflammatory cell infiltrates in the bronchi and the lung parenchyma of the infected cats. Serum amyloid A (SAA) is considered a major acute phase protein (APP) in the cat, increasing few hours after the inflammatory stimulus; also, remains elevated for as long as the inflammation persists and has shown utility as a prognostic indicator, but its usefulness in aelurostrongylosis has never been evaluated

### **Objectives:**

The objective was to determine the usefulness of SAA as a marker of lung inflammation in cats infected by *A. abstrusus*.

### **Methods:**

5 healthy cats and 6 cats infected by *A. abstrusus* participated. All infected cats were symptomatic, showing dyspnea and/or cough. Diagnosis was based on larvae detection in the fecal Baermann test. The VCHECK immunochromatography analyzer was used for the determination of SAA in fresh serum collected within 2 hours before analysis. Results were analyzed by using SPSS Base 25.0 software.

### **Results:**

Concentrations of SAA were significantly higher in infected vs healthy cats ( $18.26 \pm 12.82$  mg/L vs  $6.64 \pm 0.74$  mg/L). Furthermore, SAA concentrations were above reference values in all infected cats.

### **Conclusions:**

Pulmonary inflammation caused by *A. abstrusus* may cause the increase in SAA. The use of this APP may be useful in the diagnosis and stratification of feline aelurostrongylosis in cats showing respiratory distress. These are preliminary results and further studies are required to confirm this hypothesis.

**Topic:** AS16 Internal medicine (other)

## **URINARY PROTEOMIC STUDY IN HYPERCALCIURIC POMERANIAN DOGS WITH AND WITHOUT CALCIUM OXALATE UROLITHIASIS**

S. Chamsuwan<sup>1</sup>, K. Angkanaporn<sup>1</sup>, T. Dissayabutra<sup>2</sup>, N. Chuaypen<sup>3</sup>, T. Pisitkun<sup>4</sup>, C. Buranakarl<sup>1</sup>

<sup>1</sup>Faculty of Veterinary science, Chulalongkorn University, Department Of Physiology, Bangkok, Thailand, <sup>2</sup>STAR unit of Renal Biochemistry and Stone Disease, Faculty of Medicine, Chulalongkorn University, Department Of Biochemistry, Bangkok, Thailand, <sup>3</sup>Center of Excellence in Hepatitis and Liver Cancer, Faculty of Medicine, Chulalongkorn University, Department Of Biochemistry, Bangkok, Thailand, <sup>4</sup>Center of Excellence in Systems Biology, Research Affairs, Faculty of Medicine, Chulalongkorn University, -, Bangkok, Thailand

### **Introduction:**

Hypercalciuria can be found in both normal and dogs with CaOx stone formation. CaOx stone can induce inflammatory reaction which subsequently produce several proteins that have inhibitory or stimulatory activity on stone formation. Data of urinary proteome in hypercalciuric dogs with and without stone were scanty and the results could be useful for pathophysiology of the disease.

### **Objectives:**

To investigate the urinary proteomic profiles in Pomeranian dogs with and without CaOx urolithiasis.

### **Methods:**

Case and control study was performed in five hypercalciuric Pomeranian dogs in which stones were already removed >2 months and 5 dogs without stone. Serum and urine samples were obtained from all dogs for analysis of Ca and Mg concentrations. The urinary proteomes were analyzed using SDS-polyacrylamide gel electrophoresis and liquid chromatography mass spectrometry/mass spectrometry (LC-MS/MS). Student's t-test was used to compare the differences in concentrations of serum and urinary electrolytes and in urinary protein between groups.

### **Results:**

There were forty-nine proteins identified in urines from both hypercalciuric stone-free and CaOx urolithiasis dogs. Only thrombomodulin in stone-forming group was significantly higher ( $p=0.04$ ) than in control. The concentrations of Ca and Mg in serum and urine excretion did not difference between stone-free and CaOx dogs.

### **Conclusions:**

Urinary thrombomodulin level may be used to indicate urinary tract injury in CaOx urolithiasis.

Acknowledgement: This study was funded by the 100th Anniversary Chulalongkorn University Fund for Doctoral Scholarship and the 90th Anniversary of Chulalongkorn University Fund (Ratchadaphiseksomphot Endowment Fund). Special thanks to Ms. Nuttiya Kalpongkul for her advice and analytical work.

**P052 / #640**

**Topic:** *AS16 Internal medicine (other)*

## **EVALUATION OF CANDIDA SPP. IN THE FECES AND URINE OF DOGS WITH TYPE 1 DIABETES MELLITUS**

J. Jaffey<sup>1</sup>, S. Thangamani<sup>2</sup>, O. Okwumabua<sup>2</sup>, R. Monasky<sup>1</sup>, A. Wilson<sup>1</sup>

<sup>1</sup>Midwestern University College of Veterinary Medicine, Specialty Medicine, Glendale, United States of America, <sup>2</sup>Midwestern University College of Veterinary Medicine, Pathology And Population Medicine, Glendale, United States of America

### **Introduction:**

Type 1 diabetes mellitus (T1DM) predisposes humans to intestinal and urinary Candida spp. overgrowth. Diabetes mellitus is a common endocrinopathy in dogs, but the role of Candida spp. in this population is unknown.

### **Objectives:**

To determine if dogs with T1DM were more likely to have Candida spp. colonies isolated from feces and urine than controls.

### **Methods:**

Otherwise healthy dogs with T1DM treated with  $\geq 0.25$  units/kg of insulin, as well as healthy controls were eligible for inclusion in this prospective case-control study. Control dogs were matched by age, sex, and breed. Fecal and urine samples were collected after natural voidance. Culturing of feces and urine was performed by plating on YPD agar with antibiotics kanamycin/ampicillin/streptomycin. Identification of colonies performed with MALDI-TOF analysis. Associations and comparisons interrogated with Fisher's exact and Mann-Whitney tests, respectively.

### **Results:**

Twenty-eight dogs were enrolled (T1DM, n = 14; controls, n = 14). Dogs with T1DM were more likely to have Candida spp. colonies isolated from fecal cultures than controls (P = 0.04). Diabetic dogs had greater quantitative fungal growth from fecal cultures (P = 0.004). Female dogs were more likely to have fungal colonies isolated from feces than males, irrespective of group (P = 0.02). Fungal colonies were not obtained from any urine samples.

### **Conclusions:**

Diabetic dogs were more likely to have Candida spp. isolated and had greater quantitative fungal growth from fecal cultures than non-diabetic healthy controls. Female sex could be a contributory risk factor for fecal fungal colonization.



**P053 / #649**

**Topic:** AS16 Internal medicine (other)

## **HYPERTHYROIDISM IN A DOG WITH EXERCISE INTOLERANCE – CASE REPORT**

M. Popková<sup>1,2</sup>, O. Pomahač<sup>1</sup>, E. Pechačová<sup>1</sup>, M. Kořínek<sup>1</sup>, L. Skladanová<sup>1</sup>, J. Hnízdo<sup>1</sup>  
<sup>1</sup>Animal Clinic - Bila Hora, Internal Medicine, Prague, Czech Republic, <sup>2</sup>First Faculty of Medicine, Charles University, Department Of Physiology, Prague, Czech Republic

### **Introduction:**

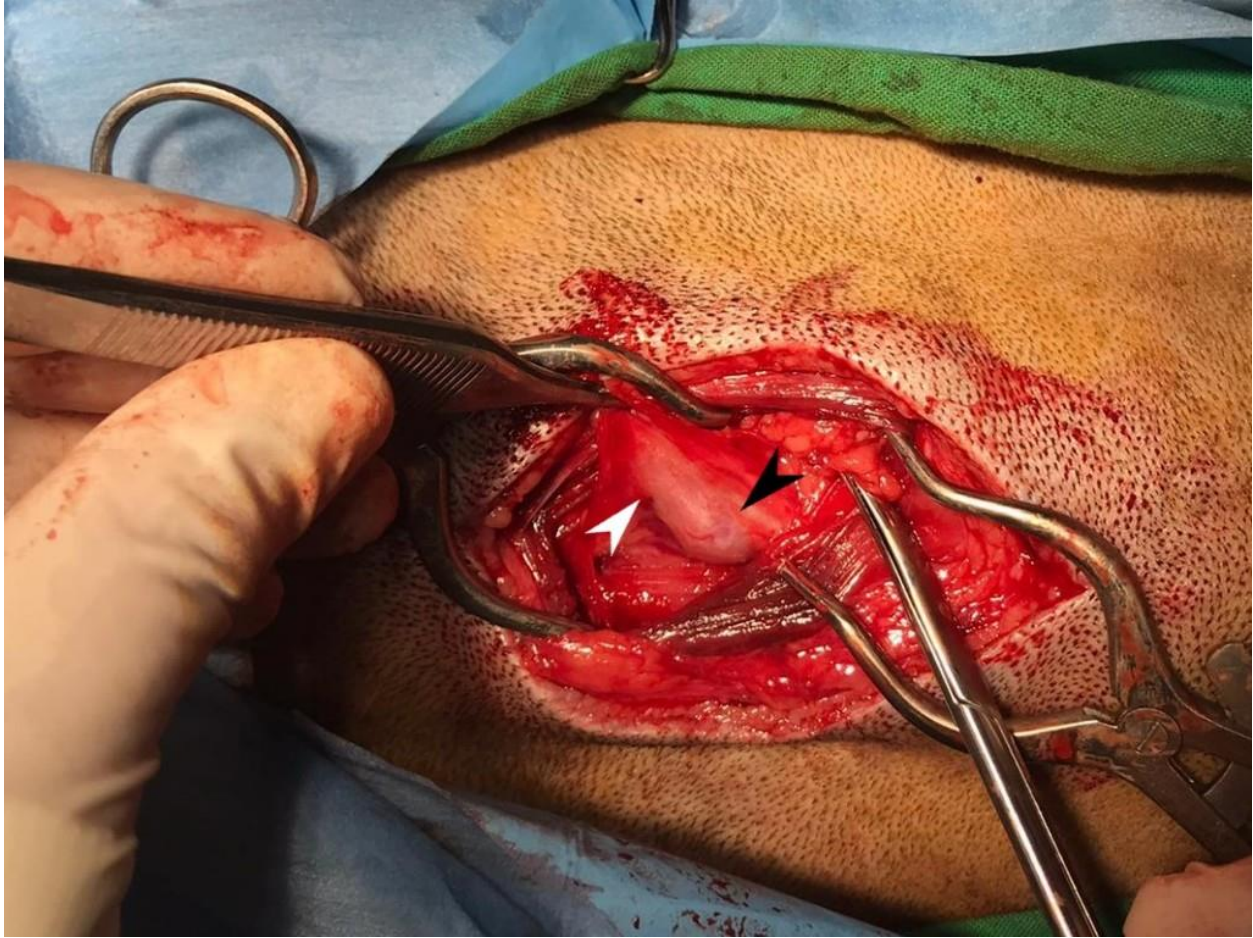
Hyperthyroidism is rare in dogs, and commonly is a consequence of inappropriate diet. Other possible causes are tumors or ectopic thyroid tissue. Hormonally active tumors in dogs are mostly adenocarcinomas which prognosis depends on size and invasiveness of the tumor as well as the presence of metastases. Here we present a case report of successful diagnosing and treatment of canine hyperthyroidism.

### **Objectives:**

A nine-year-old male Newfoundland presented exercise intolerance. Hyperthyroidism was diagnosed (tT<sub>4</sub> 58 nmol/l) with TSH (< 0.03 ng/ml) and fT<sub>4</sub> (43.5 nmol/l) within normal ranges.

### **Methods:**

Thyroid gland appeared of normal size by palpation, but ultrasonography revealed asymmetry and unilateral change in echogenicity of the thyroid gland. Contrast enhanced computed tomography evidenced a prominent unilateral thyroid nodule with same contrast enhancement as other thyroid tissue. Partial lobectomy was performed consequently.



### **Results:**

The histopathological analysis showed an adenocarcinoma with free cut borders. No signs of malignancy were found in local lymph nodes biopsies. The patient was followed weekly after the surgery to reevaluate thyroxin production and calcium-phosphate metabolism. Further oncological screenings (clinical examination, blood tests, abdominal ultrasonography, thoracic radiographs) are performed every 3 months.

### **Conclusions:**

Most dogs with thyroid gland tumors present dyspnea, dysphagia, change in barking sound, easily palpable and invasively growing tumors, having therefore poor prognosis. Our findings indicate, that if the oncological process is detected in an early stage and cured by complete resection, the prognosis is excellent. This emphasizes the importance of sensitive laboratory and imaging methods in small animal care.

**P054 / #660**

**Topic:** *AS16 Internal medicine (other)*

**DISTINCTIVE PERIPHERAL LYMPH NODE HYPERPLASIA (DPLH) IN A PERSIAN CAT (A CASE REPORT)**

A. Hatamkhani<sup>1</sup>, S. Rafatpanah<sup>2</sup>, A. Rajabi Majd<sup>3</sup>, N. Ameri<sup>4</sup>

<sup>1</sup>Nikan Pet Hospital, Tehran, Iran, Oncology Unit, Tehran, Iran, <sup>2</sup>Nikan Pet Hospital , Theran, Iran, Surgery, Tehran, Iran, <sup>3</sup>Faculty of Veterinary Medicine, University of Tehran, Internal Medicine, Tehran, Iran, <sup>4</sup>Faculty of Veterinary Medicine, University of Tehran,, Surgery And Radiology, Tehran, Iran

**Introduction:**

Lymphoma is one of the most common malignancies encountered in feline patients. In contrast to dogs with lymphoma, peripheral lymphadenomegaly is uncommon in cats.

Distinctive periphearal lymph node hyperplasia (DPLH) results in general lymphadenomegaly and should be differentiated with lymphoma. DPLH is a rare disease in cats which has been associated with feline leukemia virus infection (FeLV). In one report, only 14 cases of DPLH were diagnosed in 10 years. DPLH is most common in young cats (>2 years) and there is no sex predisposition. These animals present with peripheral lymph node enlargement with no underlying cause.

**Objectives:**

A one-year-old castrated male Persian cat was presented for evaluation of bilateral uveitis. Physical examination revealed generalized lymphadenomegaly. No improvement was observed after treatment with systemic antibiotics.



**Methods:**

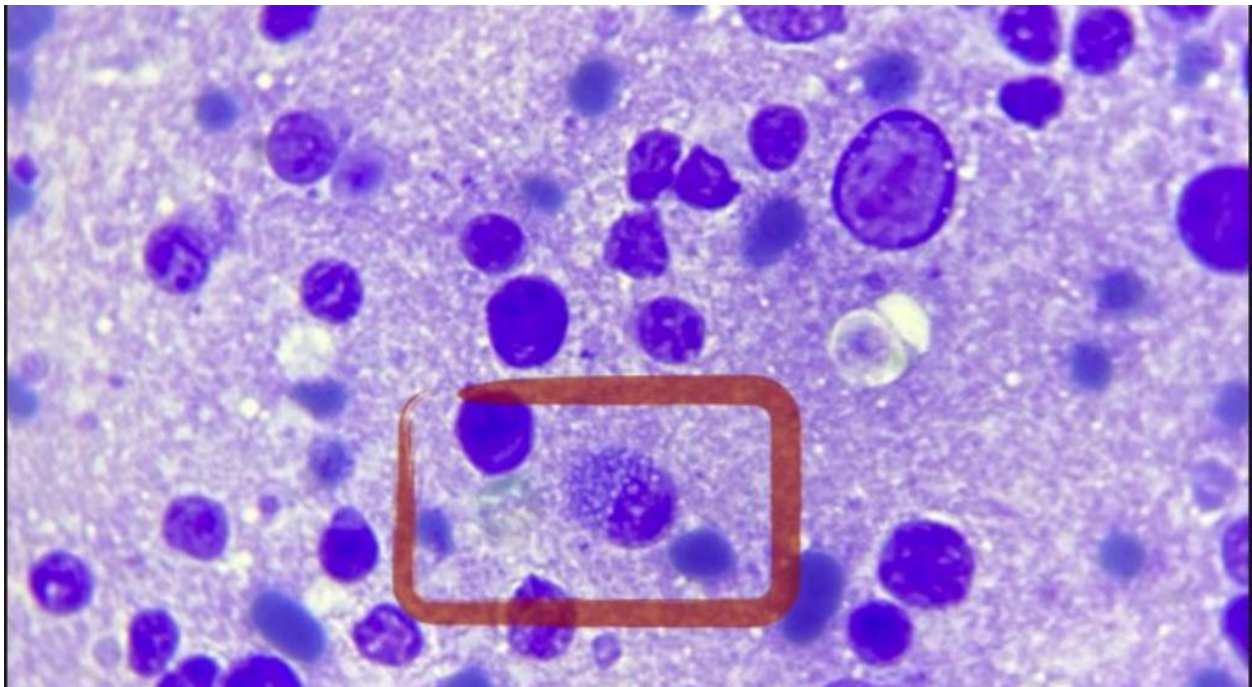


CBC, chemistry profile, Toxoplasma IgG/IgM, FIP Ag, FeLV Ag-FIV Ab, and lymph node aspiration were performed. Thoracic and abdominal radiographs and abdominal ultrasonography were also done.

### **Results:**

Results of toxoplasma, FIP, FeLV, and FIV rapid tests were all negative. Hyperglobulinemia was noted in the otherwise unremarkable blood work. Abdominal ultrasound revealed splenomegaly and mesenteric lymphadenomegaly. Treatment with meloxicam was initiated.

Lymph nodes started to decrease in size within 1 week after initiating treatment and following 4 weeks lymph nodes were within normal limits.



### **Conclusions:**

Considering the clinical presentation, laboratory and imaging findings, the presumptive diagnosis of distinctive peripheral lymph node hyperplasia (DPLH) was made.

**P055 / #662**

**Topic:** *AS16 Internal medicine (other)*

## **CLINICOPATHOLOGIC VARIABLES AND INFLAMMATORY PHENOTYPE IN DOGS WITH HEREDITARY METHEMOGLOBINEMIA BEFORE AND AFTER TREATMENT WITH ORAL METHYLENE BLUE**

J. Jaffey<sup>1</sup>, K. Wycislo<sup>2</sup>

<sup>1</sup>Midwestern University College of Veterinary Medicine, Specialty Medicine, Glendale, United States of America, <sup>2</sup>Midwestern University College of Veterinary Medicine, Pathology And Population Medicine, Glendale, United States of America

### **Introduction:**

Hereditary methemoglobinemia caused by cytochrome b5 reductase (CYB5R) deficiency is an uncommon metabolic disorder in dogs. Methemoglobin (MetHb) is an endogenous ligand for both TLR4 and TLR4/TLR2 heterodimer, which enhance proinflammatory signalling in humans. Little is known about the hematologic abnormalities or if a proinflammatory phenotype exists in dogs with hereditary methemoglobinemia.

### **Objectives:**

To determine if dogs with hereditary methemoglobinemia have a proinflammatory phenotype and describe clinicopathologic parameters before and after treatment with oral methylene blue (MB).

### **Methods:**

Dogs with hereditary methemoglobinemia caused by CYB5R deficiency confirmed via biochemical or molecular genetic testing were included in this prospective study. A second population of unaffected control dogs were included. Serum c-reactive protein (CRP) was measured using a commercially available ELISA kit. Constitutive plasma cytokine (TNF- $\alpha$ , IL-6, and IL-10) measured using a canine specific multiplex assay. Methemoglobin was measured using a NOVA blood gas analyzer with co-oximetry. Mann-Whitney tests used for group comparisons and paired t-tests for before and after MB treatment comparisons.

### **Results:**

Twenty-three (methemoglobinemic, n = 11; controls, n = 12). The median MetHb% of methemoglobinemic and control dogs was 22.8% (range, 9-36) and 1.0% (range, 0.9-1.5), respectively. Methemoglobinemic dogs had lower lymphocyte counts (P = 0.01) and MetHb% (P < 0.001) than controls. No differences were identified for plasma cytokine concentrations or CRP levels. MetHb% decreased after oral MB treatment (P < 0.001), and was the only variable to change.

### **Conclusions:**

Oral MB treatment decreases MetHb% in dogs with hereditary methemoglobinemia. Larger studies are needed to explore inflammation in methemoglobinemic dogs.

**Topic:** *AS17 Nephrology and Urology*

**EVALUATION OF BCL-2 AS A MARKER FOR PREDICTION OF CATS WITH NATURALLY OCCURRING CHRONIC KIDNEY DISEASE**

P. Pila<sup>1</sup>, P. Chuammaitri<sup>2</sup>, N. Khantaprab<sup>3</sup>, K. Pringproa<sup>2</sup>, K. Piyaungsri<sup>1</sup>

<sup>1</sup>Faculty of Veterinary Medicine, Chiang Mai University, Department Of Companion Animal And Wildlife Clinic, Chiang Mai, Thailand, <sup>2</sup>Faculty of Veterinary Medicine, Chiang Mai University, Department Of Veterinary Bioscience And Veterinary Public Health, Chiang Mai, Thailand, <sup>3</sup>Faculty of Veterinary Medicine, Chiang Mai University, Small Animal Hospital, Chiang Mai, Thailand

**Introduction:**

Chronic kidney disease (CKD) is a common disease in geriatric cats. Bcl-2 implicates kidney disease through apoptosis and fibrosis.

**Objectives:**

This study aims to compare the Bcl-2 levels between CKD and clinically healthy age-matched cats, and to determine the correlation among the Bcl-2 levels, signalment, and blood parameters of cats with CKD.

**Methods:**

Twenty-four CKD and eleven clinically healthy age-matched cats visiting the Small Animal Hospital, Faculty of Veterinary Medicine, Chiang Mai University during 2019 to 2020 were measured circulating levels of Bcl-2 by immunoassay. The Bcl-2 levels between groups were compared using a general linear model (GLM). The correlations among the circulating Bcl-2, signalment, and blood parameters were determined using Pearson correlation. The association between the survival time of CKD cats and potential variables was investigated using the Cox hazard model and Kaplan-Meier survival analysis.

**Results:**

The circulating Bcl-2 of CKD cats was significantly lower than that in clinically healthy age-matched cats ( $P = 0.034$ ). From principal component analysis (PCA), circulating Bcl-2 can distinguish CKD and healthy cats. The CKD severity was significantly positively correlated with leukocytosis but negatively correlated with anemia and body weight. The circulating Bcl-2 ( $P < 0.01$ ) and severity of CKD ( $P = 0.02$ ) were significantly associated with the survival time of cats with CKD. The area under the curve (AUC) of Bcl-2 for detection of CKD was 0.723, indicating acceptable discrimination.

**Conclusions:**

Bcl-2 concentration decrease with decreasing survival time of cats with CKD. Bcl-2 may be useful for the diagnosis of feline CKD.



**P057 / #550**

**Topic:** *AS18 Neurology/Neurosurgery*

**USE OF FRAMELESS STEREOTACTIC BRAIN BIOPSY IN DOG WITH PSEUDOMONAS MENINGOENCEPHALITIS**

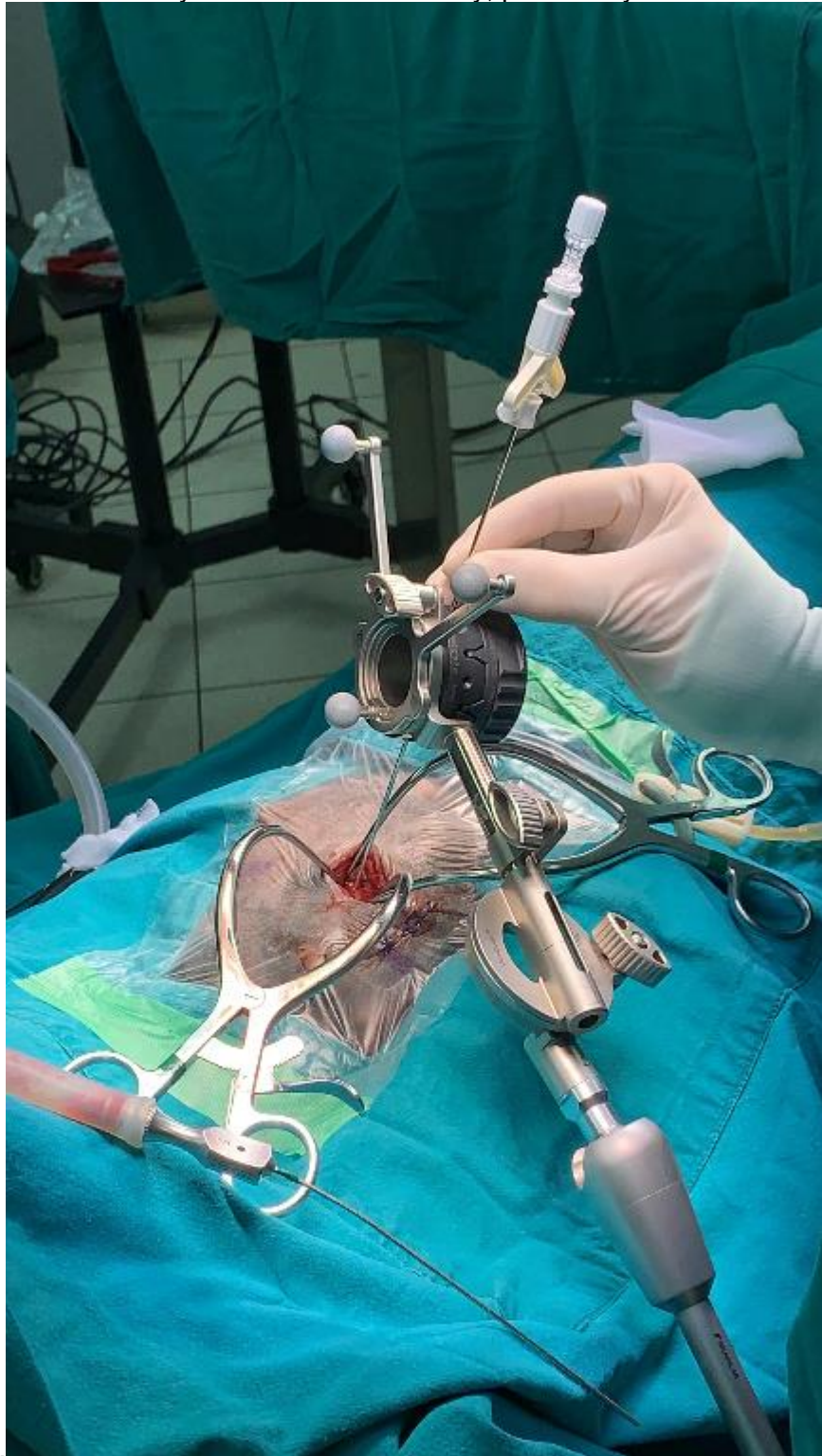K. Keadwut<sup>1</sup>, P. Lewchalermwong<sup>2</sup>, W. Theerapan<sup>3</sup>, N. Goatsang<sup>4</sup>

<sup>1</sup>Kasetsart University Veterinary Teaching Hospital, Neurological Center, bangkok, Thailand, <sup>2</sup>Kasetsart University Veterinary Teaching Hospital, Neurological Center, bangkok, Thailand, <sup>3</sup>kasetsart University Veterinary Teaching Hospital, Imaging And Radiotherapy Center, bangkok, Thailand, <sup>4</sup>Kasetsart University Veterinary Teaching Hospital, Anesthesia Center, bangkok, Thailand

**Introduction:**

Most intracranial lesions in dogs can be identified by magnetic resonance imaging (MRI) and computed tomography (CT). However, they have low specificity to define the specific underlying cause. Consequently, Frameless stereotactic brain biopsy is considered to surgical approach as

they minimize injury, preserve healthy brain and little mortality, particularly some lesion located



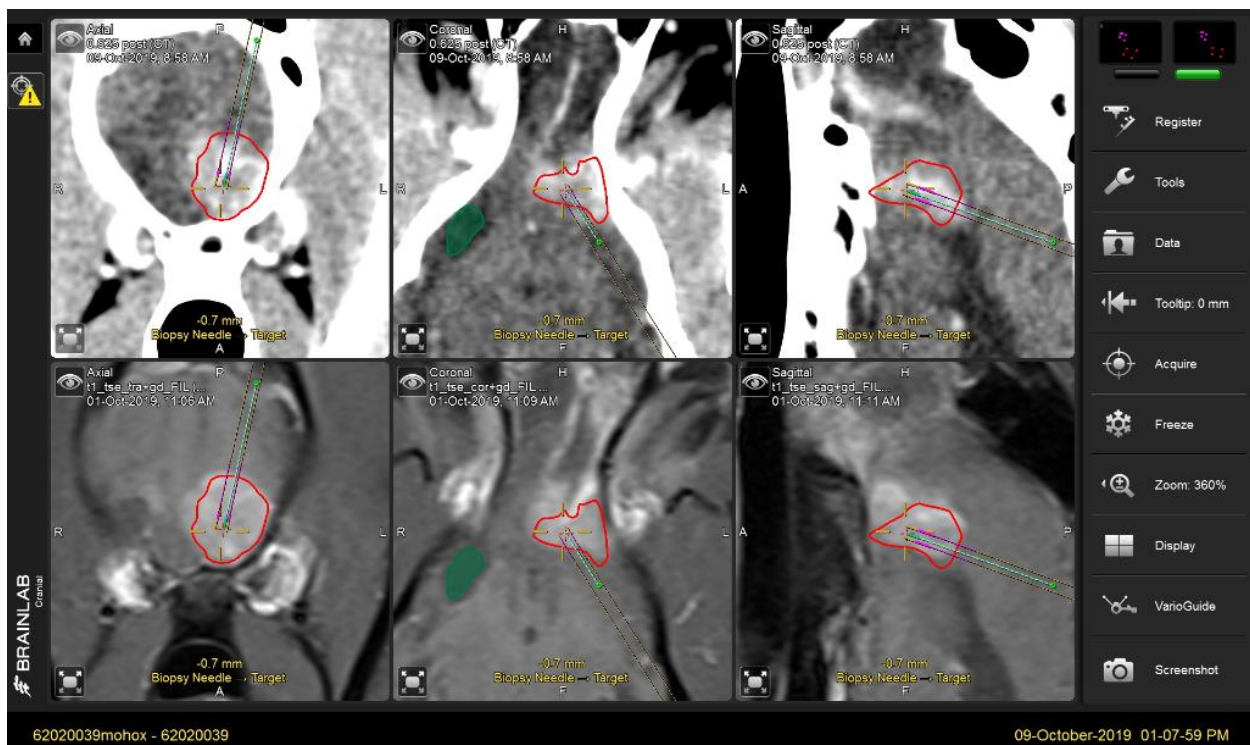
in the deep brain area.

**Objectives:**

To report a case study, which used a frameless stereotactic brain biopsy for the definitive diagnosis of unknown intracranial lesions in a dog.

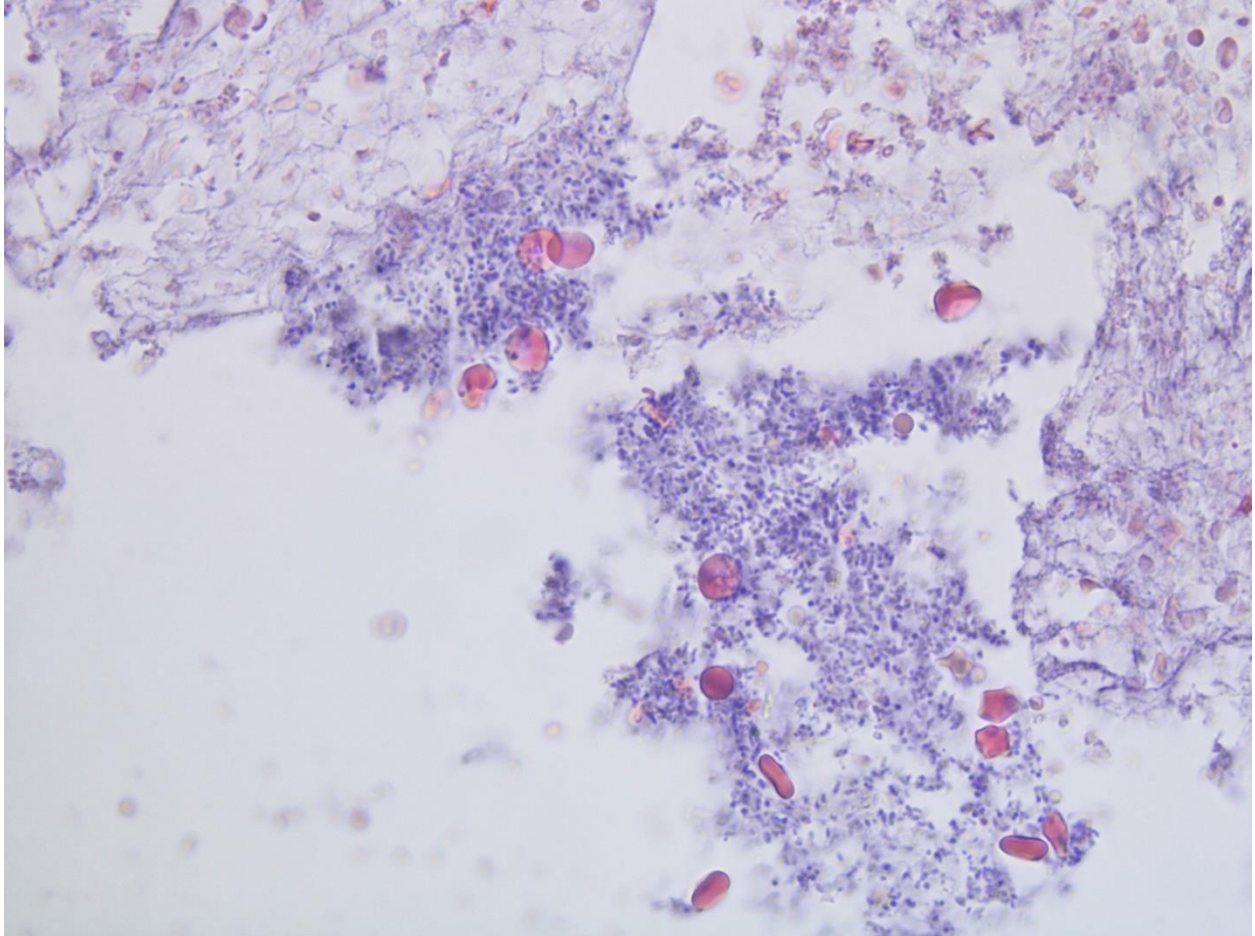
## Methods:

A 4-years-old intact male crossbreed dog was presented for evaluation of seizure, left wide circling, and aggressive behavior after operation for both eyes enucleation 1 month ago. MRI demonstrated the left cranio-frontal brain mass located in the skull base area and near to the lateral ventricle which may have a high risk of healthy tissue damage from direct surgery. Then, a frameless stereotactic was performed for brain biopsy. Histopathological findings showed necrotic debris, red blood cells, and rod-shaped bacteria. Sample's culture revealed *Pseudomonas* ( $2.6 \times 10^2$ CFU/ml) which was susceptible to enrofloxacin. Thus, it was prescribed continuously 8 weeks after surgery.



## Results:

After eight weeks of surgery and medical management, the clinical signs of aggressive behavior improved, and non-detected seizure. MRI postoperatively demonstrated the change at the left cranio-frontal area from contrast enhancement to mineralization and fluid accumulation.

**Conclusions:**

In this case, MRI results could not differentiate between the inflammatory brain and tumor disease. Thus, frameless stereotactic biopsy provided the definitive diagnosis that leads to an efficient treatment.

**P058 / #641**

**Topic:** *AS19 Nutrition*

## **THE EFFECT OF DIET ON IMMUNE FUNCTION AND INFLAMMATORY PHENOTYPE IN DOGS**

J. Jaffey<sup>1</sup>, D. Su<sup>2</sup>, R. Monasky<sup>1</sup>, B. Hanratty<sup>1</sup>, E. Flannery<sup>1</sup>, M. Horman<sup>1</sup>

<sup>1</sup>Midwestern University College of Veterinary Medicine, Specialty Medicine, Glendale, United States of America, <sup>2</sup>Just Food For Dogs, LLV, Veterinary Nutrition, Los Angeles, United States of America

### **Introduction:**

An increasing number of pet owners are seeking alternative pet food options to standard commercial kibble diets and cooked, whole food diets (WFD) have emerged as an alternative. Whole foods in humans have anti-inflammatory effects and augment immune function but this has not been explored in dogs.

### **Objectives:**

To determine if feeding a balanced WFD improves immune function or decreases inflammation compared to extruded commercial kibble diets (KD).

### **Methods:**

Healthy dogs were eligible for this prospective, randomized, open-labelled, cross-over design study. Dogs were randomized to initially be offered a WFD or their maintenance commercial KD for 67 days in Phase I and then were offered the opposite food type for 67 days in Phase II (total study length 134 days). Blood for immunologic testing was obtained at baseline and the end of each phase. Serum c-reactive protein (CRP) was measured using a commercially available ELISA assay. Whole blood cultures were performed with exposure to PBS, LPS, and LTA. Canine specific multiplex assay was used to measure TNF- $\alpha$ , IL-6, and IL-10 concentrations. Phagocytosis and oxidative burst were evaluated via flow cytometry. Data were compared using Mann-Whitney Rank Sum tests.

### **Results:**

Sixteen dogs were included. Dogs fed a WFD had lower LTA-stimulated TNF- $\alpha$ :IL-10 ratios than KD ( $P = 0.03$ ). There were no differences in the remaining TNF- $\alpha$ :IL-10 ratios, individual stimulated cytokine (TNF- $\alpha$ , IL-6, and IL-10) concentrations, CRP levels, or phagocytosis/oxidative burst between the two food types.

### **Conclusions:**

Whole food diets could have anti-inflammatory effects in dogs and warrants additional investigation.



**P059 / #576**

**Topic:** *AS20 Oncology*

**DIFFERENTIAL EXPRESSION OF TYR, CD34, AND CALD1 DISCRIMINATES BETWEEN CANINE ORAL MALIGNANT MELANOMAS AND SOFT TISSUE SARCOMAS**

M. Tsoi, T. Thaiwong, R. Smedley, E. Noland, M. Kiupel  
Michigan State University, Department Of Pathobiology And Diagnostic Investigation, Lansing,  
United States of America

**Introduction:**

Melanomas are the most common malignant neoplasms in the oral cavity of dogs that exhibit a wide variety of histologic phenotypes, including a spindloid variant. Microscopic differentiation of spindloid amelanotic melanomas from soft tissue sarcomas (STS) is very difficult in the absence of key diagnostic features such as intraepithelial nests. Previously, immunohistochemistry (IHC) using an antibody cocktail that detects Melan-A, PNL2, TRP-1 and TRP-2 has been established as the gold standard for diagnosing oral melanomas (OM) with 100% specificity and 93.9% sensitivity. However, positive labelling less commonly occurred in spindloid amelanotic melanomas.

**Objectives:**

To establish quantitative RNA expression profiles that accurately diagnose oral spindloid amelanotic neoplasms as OM or STS.

**Methods:**

Formalin-fixed, paraffin-embedded tissues from 20 OM, 20 STS, and 20 oral spindloid amelanotic neoplasms were selected and IHC for the antibody cocktail, SOX-10 and laminin, in parallel with RT-qPCR of TYR, SOX10, CALD1, CD34, DES, and LAMA1, was performed on all cases.

**Results:**

Quantitative expression of TYR, CD34, and CALD1 differentiated OM from STS, with 100% specificity and 65%, 95%, and 60% sensitivity, respectively. All 20 OM were positive for SOX-10, however, two STS were also positive (100% sensitivity, 90% specificity). Surprisingly, none of the 20 oral spindloid amelanotic neoplasms had RNA expression profiles or IHC patterns consistent with a diagnosis of melanoma.

**Conclusions:**

RNA levels of TYR, CD34 and CALD1 should be evaluated in oral spindloid amelanotic neoplasms that are negative for the antibody cocktail to accurately differentiate between OM and STS.

**Topic:** *AS20 Oncology*

## **DIAGNOSIS AND STAGING OF CANINE MULTICENTRIC LYMPHOMA: CONCEPT OF STAGE MIGRATION**

T. Pinto<sup>1</sup>, I. Portillo<sup>2</sup>, J. Borrego<sup>2</sup>, F. Queiroga<sup>3</sup>

<sup>1</sup>Member of the Royal College of Veterinary Surgeons, Sn, sn, United Kingdom, <sup>2</sup>Aúna Especialidades Veterinarias, S/n, Valencia, Spain, <sup>3</sup>Universidade de Trás-os-Montes e Alto Douro, Veterinary Sciences, Vila Real, Portugal

### **Introduction:**

Canine multicentric lymphoma is usually staged as stage I through V based on the anatomic site(s) affected and substage a or b based on presence of clinical signs tumor related.

### **Objectives:**

The aim of this study was to evaluate the impact of different diagnostic techniques in its staging and to determine whether multiple staging methods result in significant stage migration (change to both lower or higher disease stages due to the use of more sensitive staging tests).

### **Methods:**

Dogs cytologically diagnosed with multicentric lymphoma were staged using four different staging methods (A-D): A (physical examination, hemogram, blood smear), B (A plus thoracic X-ray, abdominal ultrasound), C (B plus liver and spleen cytology) and D (C plus bone marrow cytology).

### **Results:**

Twenty-three dogs were enrolled: 16 females (70%) and 7 males (30%). Regarding immunophenotype, 21 dogs (91,3%) were B-cell and 2 dogs (8,7%) were T-cell. Stage migration was observed between all staging methods. Between A and B, 12 animals migrated from stage III to stage IV. Between B and C, 4 animals migrated, 3 to a higher stage (stage III to IV) and 1 to a lower stage (stage IV to III). Between C and D, 1 animal migrated from stage IV to V. The differences between staging methods A and B were statistically significant ( $P \leq 0,001$ ).

### **Conclusions:**

The results of this study show that applying standardized staging methods would be helpful in order to avoid stage migration, which is a phenomenon that hinders the accurate comparison of results obtained in different studies.

**P061 / #597**

**Topic:** *AS20 Oncology*

### **C.3140A>G MUTATION OF PIK3CA GENE AS A PROGNOSTIC FACTOR IN CANINE MAMMARY CANCER**

I. Perossi<sup>1</sup>, M. Saito<sup>2</sup>, G. Varallo<sup>2</sup>, J. Colombo<sup>2</sup>, D. Zuccari<sup>2</sup>

<sup>1</sup>IBILCE/UNESP, Biociências, São José do Rio Preto, Brazil, <sup>2</sup>FAMERP, Limc, São José do Rio Preto, Brazil

#### **Introduction:**

Breast cancer is the most prevalent tumor type among women and dogs are considered models for the study of this neoplasm, as they share many similarities with humans. The PIK3CA/AKT/mTOR pathway is strongly unregulated in cancer and the PIK3CA gene, with emphasis on the mutation c.3140A>G, which is a non-silent mutation that can alter protein expression.

#### **Objectives:**

Analyze the c.3140A>G variant of the PIK3CA gene in fragments of dogs with mammary cancer (MC) and correlate it with the expression of the PIK3CA protein, as well as with prognostic factors using the PARP-1, ZEB2 and HIF proteins.

#### **Methods:**

The DNA and ctDNA of tumor fragments and plasma from 38 dogs with MC were extracted using the AllPrep® DNA/RNA/Protein Mini Kit (Qiagen, Hilden, Germany) and QIAmp Circulating Nucleic Acid Kit (Qiagen®), respectively and later Next Generation Sequencing performed. In addition, DNA was extracted from 26 MC and 20 normal canine mamma and the mutation was verified using TaqMan® Mutation Detection Assays. Immunohistochemistry was performed using the Reveal HRP Conjugate kit (Spring®) and its analysis using the Histoscore method.

#### **Results:**

Two patients had the c.3140A>G mutation, of which one had pulmonary metastasis and died within 30 days, the other has been followed-up for 300 days. The expression of PIK3CA protein was higher in patients with the mutation compared to patients without the mutation ( $p<0.05$ ).

#### **Conclusions:**

The c.3140A>G mutation of the PIK3CA gene alters the expression of the PIK3CA protein. This protein, PARP-1, ZEB2 and HIF are related to poor prognosis and shorter survival of their carriers.



**P062 / #623**

**Topic:** *AS20 Oncology*

## **EVALUATION OF EPIDEMIOLOGICAL AND CLINIC FEATURES OF CANINE MAST CELL TUMOURS: IMPACT ON DISEASE FREE AND OVERALL SURVIVAL**

A.F. Vaz<sup>1</sup>, G. Petrucci Maurício<sup>2</sup>, F. Queiroga<sup>3</sup>

<sup>1</sup>universidade de Trás-os-Montes e Alto Douro, Ciências Veterinárias, Msc Student, Vila Real, Portugal, <sup>2</sup>Onevetgroup, Hospital Veterinário Do Porto, Veterinary Sciences, Dvm, Phd Student,, Porto, Portugal, <sup>3</sup>Universidade de Trás-os-Montes e Alto Douro, Veterinary Sciences, Vila Real, Portugal

### **Introduction:**

Mast cells tumors are common skin tumours in dogs. Despite the number of studies on the topic, several clarifications are still needed regarding the prognostic impact of some epidemiological, clinic and pathological characteristics as well the effect of distinct treatment protocols on survival

### **Objectives:**

This retrospective study aims to evaluate which epidemiological and clinical variables are significantly associated with tumor grade (Patnaik and Kiupel), Disease-free Survival and Overall Survival.

### **Methods:**

Fifty-four dogs diagnosed by cytology and/or histopathology were staged according to WHO. The variables included were: gender, age, breed, tumour location, size, margins, ulceration, mitotic index, tumor grade, staging, recurrence and treatment. DFS and OS times were estimated by Kaplan-Meyer.

### **Results:**

Kiupel grade was associated with a decreased DFS ( $p<0,01$ ), and both patnaik ( $p=0,04$ ) and kiupel ( $p<0,01$ ) were associated with a decreased OS. Tumor Location was associated with patnaik grade ( $p=0,05$ ), DFS ( $p<0,01$ ) and OS ( $p=0,01$ ). Clinical stage I was associated with lower kiupel grades ( $p<0,01$ ) and increased OS ( $p=0,01$ ). Recurrence ( $p=0.02$ ), age ( $p=0,04$ ) and ulceration ( $p=0.02$ ) had a negative association with OS. Cases treated with both surgery and chemotherapy had a decreased DFS ( $p<0,01$ ) and OS ( $p=0.03$ ), while cases treated with surgery had a better prognosis.

### **Conclusions:**

High grade (Kiupel) or grade III (Patnaik), advanced staging, mitotic index, labial and/or perineal location, age between 7-12 years, ulceration and recurrence arise as negative prognostic factors, associated to decrease DFS and OS times. Clinicians should be aware of these features in order to adjust therapeutic plans and monitoring.

**P063 / #659**

**Topic:** *AS20 Oncology*

## **ELECTROCHEMOTHERAPY TREATMENT APPROACH FOR FELINE NASAL SQUAMOUS CELL CARCINOMA - A RETROSPECTIVE STUDY**

M. Jardim Fernandes<sup>1</sup>, J. Martins<sup>2</sup>, A. Figueira<sup>1,3</sup>, J. Henriques<sup>2,4</sup>, G. Petrucci Maurício<sup>2,5</sup>

<sup>1</sup>Escola Universitária Vasco da Gama, Veterinary Sciences Department, Coimbra, Portugal, <sup>2</sup>Hospital Veterinário de Berna, Oncology, Lisboa, Portugal, <sup>3</sup>Hospital Veterinário Universitário de Coimbra, Oncology, Coimbra, Portugal, <sup>4</sup>Centre Hospitalier Vétérinaire Frégis, Oncology, Arcueil, France, <sup>5</sup>Hospital Veterinário do Porto, Oncology, Porto, Portugal

### **Introduction:**

Squamous cell carcinoma (SCC) is the third most common skin tumor in cats and several treatment modalities are suggested for tumor control. Electrochemotherapy (ECT) combines the administration of specific chemotherapeutic drugs with electrical pulses, has been suggested as a potential nasal planum SCC (npSCC) treatment. However, only a few studies are reported in literature.

### **Objectives:**

This retrospective study aims to evaluate ECT treatment's efficacy and safety in cats with npSCC.

### **Methods:**

For inclusion, cats must have a histopathological or cytological diagnosis of npSCC and at least one ECT treatment and respective follow-up. All cats were stage according to WHO guidelines. Treatment response was evaluated following RECIST. Treatment side effects were recorded. Study endpoints were overall response rate (RR), progression-free survival (PFS) and overall survival (OS).

### **Results:**

Twenty-nine cats were included and submitted to ECT, combining bleomycin intravenously in 27 animals and cisplatin intralesional in 2 animals. The RR was 75.9%, 34.5% had local necrosis and 31% didn't show any side effects. Sneezing, anorexia and nasal discharge (20.6%) were the most common. The mean of PFS was 245 days and the mean of OS was 709 days (median not achieved). The development of necrosis after ECT was considered a negative prognostic factor for both PFS ( $p = 0.032$ ) and OS ( $p = 0.001$ ). Tumor size was also considered a negative prognostic factor for OS ( $p = 0.041$ ).

### **Conclusions:**

ECT is an effective and safe treatment for small npSCC and can be used as an alternative to surgery or radiotherapy, with tolerable side effects.

**P064 / #519**

**Topic:** *AS21 One health*

## **INVESTIGATION OF COVID 19 PANDEMIC RELATED CHALLENGES IN IMPLEMENTING ANTIMICROBIAL STEWARDSHIP IN UK COMPANION ANIMAL PRACTICES.**

A. Turley, D. Subasinghe

University of Surrey, Clinical Sciences, Guildford, United Kingdom

### **Introduction:**

Antimicrobial stewardship in companion animal practice is key to reducing antibiotic resistance development. Covid-19 changed the way we practice in 2020-21.

### **Objectives:**

This pilot study explored the challenges faced by companion animal veterinarians in the UK (where several lockdowns affected practice services drastically) regarding antimicrobial stewardship protocols.

### **Methods:**

An online anonymised Jisc® survey was used for data collection from February to March 2021. Data was gathered on veterinarian's personal opinions using dichotomous questions and Likert scales. The questions also included Covid-19 related telemedicine practices. Data was analysed using SPSS software and Chi squared test.

### **Results:**

Sixty-five responses were received. 51.6% of participants did not think their prescribing of antimicrobials were best practice due to the online nature of client communications. Participants said that they were more likely to prescribe antibiotics without a clinical examination during the pandemic (77%) than they would have done before (23%). Client communication moving to online or phone conversations was found to be a major challenge together with the inability to perform physical examinations.

### **Conclusions:**

These factors in the participants opinion led to inadequate specific diagnoses. This then led to inability to follow best practice principles for prescribing antibiotics. Specifically, when clients themselves were categorised as clinically vulnerable and needed to self-isolate, vets felt pressured to prescribe antimicrobials in the absence of evidence such as culture and sensitivity testing. This study is ongoing and provides an insight into the challenges faced during the pandemic and the need to explore ways around these challenges as the pandemic continues.

**Topic:** AS21 *One health*

## **DETECTION OF METHICILLIN-RESISTANT STAPHYLOCOCCUS SPP. STRAINS ISOLATED FROM DOGS AND CATS IN CHILE**

P. Thomson<sup>1</sup>, A. Núñez<sup>2</sup>, P. García<sup>3</sup>

<sup>1</sup>Laboratorio de Microbiología Clínica y Microbioma. Escuela de Medicina Veterinaria, Facultad De Ciencias De La Vida, Universidad Andrés Bello, Laboratorio, Chile, <sup>2</sup>Universidad Santo Tomás, 2facultad De Recursos Naturales Y Medicina Veterinaria. Escuela De Medicina Veterinaria., Talca, Chile, <sup>3</sup>Pontificia Universidad Católica de Chile, Departamento De Laboratorios Clínicos, Escuela De Medicina, Santiago, Chile

**Introduction:** Antimicrobial resistance (AMR) has become a threat to human and animal health. Infections with resistant bacteria lead to increased morbidity, mortality, and longer hospitalizations. *Staphylococcus* spp. It is a Gram-positive bacterial that affects both people and animals, however, in recent years a significant number of antibiotic-resistant strains have been detected. Intrinsic resistance to methicillin in strains of *Staphylococcus* spp. it is described as the main mechanism of resistance to  $\beta$ -lactams and the most important from the clinical point of view.

**Objectives:** The objective of this study was to detect and identify the presence of *Staphylococcus* spp. methicillin-resistant isolates from dogs and cats.

**Methods:** Sampling was performed from the nostrils of healthy dogs (61) and cats (61). Each sample was sown on mannitol salt agar and blood agar. The different morphotypes were identified by MALDI-TOF and the antimicrobial susceptibility was determined by the disk diffusion method.

**Results:** The majority of coagulase positive and coagulase negative *Staphylococcus* strains were identified. The methicillin resistance phenotype was detected in 25% of dogs and 57.1% of cats

**Conclusions:** A high percentage of coagulase negative *Staphylococcus* was detected, as well as a resistance phenotype greater than 25% in dogs and cats. A greater understanding of antibiotic use practices and the dynamics of AMR in animals and the role they can play in the possible spread of AMR to humans is needed. In addition to raising awareness about the existence of these strains and their implication in animal and human health.

**Topic:** AS22 *Ophthalmology*

**CASE REPORT: CATARACT IN A HYPOCALCEMIC DOG WITH IDIOPATHIC HYPOPARATHYROIDISM**

R. Lombardi<sup>1</sup>, B. Lamagna<sup>2</sup>, S. Albarella<sup>2</sup>, M. Pugliano<sup>2</sup>, L. Cortese<sup>2</sup>, G. Flauto<sup>3</sup>, M. Iule<sup>4</sup>, C. Di Palma<sup>2</sup>

<sup>1</sup>Freelance, Veterinary Ophthalmology, Rome, Italy, <sup>2</sup>University of Naples "Federico II", Department Of Veterinary Medicine And Animal Production, Naples, Italy, <sup>3</sup>ASL, Napoli 2 Nord, MARANO, Italy, <sup>4</sup>Veterinary Hospital, "nuovo Ospedale Veterinario Ardeatino", Rome, Italy

**Introduction:**

Calcium homeostasis plays a key role in cataractogenesis in patients with idiopathic hypoparathyroidism. In humans and mice, genetic mutations responsible of gain of function of extracellular calcium-sensing receptor (CaSR) may cause hypocalcemia and cataract. In the lens, the activation of CaSR causes an accumulation of inositol 1,4,5-triphosphate and an intracytoplasmic release of Ca<sup>2+</sup> from the endoplasmic reticulum. Studies about CaSR gene in dogs with hypocalcemia and cataract are not reported.

**Objectives:**

To describe a case of idiopathic hypoparathyroidism associated with cataracts in a dog.

**Methods:**

A 4-years old male mixed-breed dog was referred because of muscular spasms, tremors, and vomiting. Clinical, hematological, and ophthalmic examinations and computed tomography were performed. A sample of blood was collected for genetic tests.

**Results:**

The most important changes in blood tests were hypocalcemia (6 mg/dl; range 9,7-10,8 mg/dl) and a decrease in serum PTH (3 pg/ml; range 10-44 pg/ml). The medical history, clinical signs, and laboratory examinations confirmed the diagnosis of idiopathic hypoparathyroidism. Initial intravenous treatment was performed with calcium gluconate, and then calcitriol and calcium carbonate orally were used as maintenance therapy. At the time of ophthalmic examination, the right eye presented a mature cataract, while a multifocal posterior subcapsular cataract was diagnosed in the left eye. The owners rejected cataract surgical treatment.

**Conclusions:**

We described a case of idiopathic hypoparathyroidism associated with cataracts in a dog. As in humans and mice, hypoparathyroidism could be associated with genetic mutations. Therefore, we investigate the CaSR gene for the first time in dogs looking for polymorphisms altering its functionality.

**P067 / #612**

**Topic:** AS22 *Ophthalmology*

**COMPARISON OF THE ANTI-INFLAMMATORY EFFECT AND TEAR STABILITY USING CHONDROITIN SULFATE AND SODIUM HYALURONATE EYE DROPS IN DOGS WITH DRY EYE.**

F. Wouk<sup>1</sup>, L. Castanho<sup>2</sup>, J. Kleiner<sup>1</sup>, D. Pereira<sup>2</sup>

<sup>1</sup>Federal University of Parana, Veterinary Medicine, Curitiba, Brazil, <sup>2</sup>Batel Veterinary Hospital, Ophthalmology, Curitiba, Brazil

**Introduction:**

Metalloproteinase-9 (MMP-9) breaks corneal barrier function in dogs with dry eye. The immunoassay (InflammaDry®) detects elevated tear MMP-9 is used for clinical diagnosis of dry eye in humans. Topical CS and HA has been reported to suppress inflammatory markers. Sodium hyaluronate is a pseudoplastic fluid unlike chondroitin sulfate, which is a Newtonian fluid. Newtonian eyedrops retain a constant viscosity during all phases of blinking.

**Objectives:**

Compare the anti-inflammatory effect of topical CS and HA by detection of tear MMP-9 and compare tear stability by the Tear Film Break-up-Time (TFBUT), Schirmer Tear Test (STT) and Lissamine green vital corneal staining.

**Methods:**

In a randomized study, a Control group of 6 dogs, were evaluated weekly from day zero to 21 (InflammaDry® test, TFBUT, STT, Lissamine green) and treated, three dogs with topical 20% CS (Tears-Labyes®) and the others with topical 0,4 % HA (Adaptis Fresh-Legrand®). A dry eye group of 12 dogs were evaluated, distributed (6 Tears and 6 Adaptis fresh) and treated similarly.

**Results:**

Control group: InflammaDry and Lissamine tests were negative, other tests didn't show significant modifications. Dry eye group HA: tiny rising TFBUT only at 21 days, negative for Lissamine green at day 14 and four dogs positive for InflammaDry test till day 14; CS group: from day seven to 21 a significant progressive TFBUT rising (plus 3.5 seconds), negative Lissamine green and InflammaDry tests.

**Conclusions:**

In comparison with 0,4% HA, 20% CS eyedrops inhibits earlier MMP-9 and so has more marked anti-inflammatory effect and also produces tear film stability earlier.

**Topic:** AS23 Orthopedics

## **DIFFERENCES BETWEEN SAFE ANATOMICAL CORRIDORS FOR EXTERNAL SKELETAL PIN INSERTION – BRACHIUM OF THE CAT AND RABBIT**

I. Pračková<sup>1,2</sup>, V. Páral<sup>2</sup>, M. Kyllar<sup>2,3</sup>

<sup>1</sup>Masaryk University, Department Of Anatomy, Brno, Czech Republic, <sup>2</sup>University of Veterinary Sciences Brno, Department Of Anatomy, Histology And Embryology, Brno, Czech Republic, <sup>3</sup>University of Veterinary Medicine, Institute Of Morphology, Vienna, Austria

### **Introduction:**

External skeletal fixation (ESF) is a well known technique in veterinary medicine used to treat fractures. The successful use of external skeletal fixation depends on knowledge of the cross-sectional limb anatomy. Safe anatomical corridors for ESF pin insertion have not been fully described in cats and rabbits and veterinarians often use corridors for canine patients, although their anatomy is different.

### **Objectives:**

The aim of this study is to find, describe and compare safe corridors for ESF pin insertion in cat and rabbit brachium.

### **Methods:**

Five feline and five rabbit cadavers were used. Their forelimbs were deep frozen at -14 degrees. Frozen forelimbs were horizontally cut, anatomical structures and safe corridors for ESF pin insertion were described on forelimb cross-sections in both species.

### **Results:**

There are important differences in topographic and cross-sectional anatomy of the brachium in cats and rabbits.

Cat: safe corridors in brachium were located at proximal craniolateral side and on the lateral humeral epicondyle.

Rabbit: safe corridors in brachium were located at proximal craniolateral side and on the lateral and medial humeral epicondyle.

### **Conclusions:**

It is important to study safe corridors for ESF pin insertion individually for each animal species because the anatomy of cat and rabbit is different and use of inappropriate corridors during surgery can cause iatrogenic injury.

**P069 / #545**

**Topic:** AS24 Other

## **INCREASED PREVALENCE OF METHICILLIN RESISTANT STAPHYLOCOCCI IN PETS OVER THE PAST DECADE**

E. Spagnolo<sup>1</sup>, M. Berlanda<sup>2</sup>, I. Drigo<sup>1</sup>, K. Trevisiol<sup>1</sup>, M. Cocchi<sup>1</sup>, R. Perin<sup>1</sup>, S. Deotto<sup>1</sup>, D. Pasotto<sup>2</sup>, M. Corrò<sup>1</sup>

<sup>1</sup>Istituto Zooprofilattico Sperimentale delle Venezie, Sanità Animale, Legnaro (PD), Italy, <sup>2</sup>Università degli Studi di Padova, Dipartimento Di Medicina Animale, Produzioni E Salute, Legnaro (PD), Italy

### **Introduction:**

Coagulase positive Staphylococci (CoPS) belong to human and animal saprophytic bacterial flora and are usually associated with skin and mucosal infections in pets. Over the last years, the diffusion of Methicillin Resistant Coagulase Positive Staphylococci (MRCoPS) has reached worrying levels in terms of public health; since many of them are multi-resistant. The presence of MRCoPS in pets could lead therapeutic failure and could be a source of contamination.

### **Objectives:**

To evaluate the prevalence of MRCoPS isolated from animals over the past decade.

### **Methods:**

Two investigations were compared to determine the prevalence of MRCoPS isolated from clinical samples and analysed at the diagnostic laboratory of the Istituto Zooprofilattico Sperimentale delle Venezie. The studies were carried out between 2011-2014 and 2019-2021. An overlapping number of samples from dogs and cats suffering from skin and mucosal infections was analysed. MRCoPS colonies were isolated by bacteriological examination and the presence of methicillin resistance gene (*mecA*) was confirmed by PCR. Bacterial species were identified by mass spectrometry.

### **Results:**

In the first study, CoPS were isolated from 24.3% of animals while in the second from 35.7%, respectively 5.1% and 20% were methicillin resistant. Statistical analysis confirmed a significant difference in MRCoPS prevalence between the two study periods ( $p < 0.0001$  C.I.99%). In addition, CoPS were predominant in dogs with respect to cats; among them, the prevalent species was *Staphylococcus pseudintermedius*.

### **Conclusions:**

This relevant increase in methicillin resistant strains could be due to a wider use of antibiotics and resistance genes exchanges between bacteria.



**P070 / #617**

**Topic:** AS24 Other

## **AGE, BREED, SEX, AND DIET INFLUENCE SERUM METABOLITE PROFILES OF 2000 PET DOGS**

J. Puurunen<sup>1,2,3,4</sup>, C. Ottka<sup>1,2,3,4</sup>, M. Salonen<sup>2,3,4</sup>, J.E. Niskanen<sup>2,3,4</sup>, H. Lohi<sup>1,2,3,4</sup>

<sup>1</sup>PetBiomix Ltd, Na, Helsinki, Finland, <sup>2</sup>University of Helsinki, Department Of Veterinary Biosciences, Helsinki, Finland, <sup>3</sup>University of Helsinki, Department Of Medical And Clinical Genetics, Helsinki, Finland, <sup>4</sup>Folkhälsan Research Center, Na, Helsinki, Finland

### **Introduction:**

Metabolomics is the comprehensive investigation of metabolism in a biological system. Since an individual's metabolism reflects health and disease states well, metabolomics holds vast potential in gaining understanding of both normal physiology and multifactorial diseases. However, it is vital to understand the metabolic effects of basic physiological characteristics, such as age or breed of the individual, to be able to separate them from metabolic alterations caused by pathological processes.

### **Objectives:**

To investigate how physiological and diet-related factors influence canine metabolism.

### **Methods:**

We analysed serum samples of 2068 evidently healthy pet dogs using a canine-specific nuclear magnetic resonance spectroscopy metabolomics platform, which quantitates 123 metabolite measurands. We examined the effects of age, breed, sex, sterilisation, body size, diet, and fasting time before blood sampling on the measurand levels with generalised linear models and set false discovery rate corrected significance threshold at  $p < 0.05$ .

### **Results:**

Age, breed, sex, sterilisation, diet, and fasting time profoundly affected canine metabolism, and the observed effects were largely measurand-specific. Breed and age caused considerable variation in the measurand concentrations, and breeds with very different body conformations systematically differed in their levels of several lipid measurands. However, only a few changes exceeded or undercut the established reference intervals.

### **Conclusions:**

This study provides a solid foundation for understanding how physiological factors affect canine metabolism. Our results stress the importance of controlling physiological factors in study designs and statistical analyses when conducting metabolomics studies, and improves interpretation of the canine NMR metabolomics platform results.

Topic: AS24 Other

## DIFFERENCES OF THE INTESTINAL MICROBIOME BETWEEN OBESE DOGS AND NORMAL WEIGHT, USING NEXT-GENERATION SEQUENCING

P. Thomson<sup>1</sup>, C. Flores<sup>2</sup>, R. Santibáñez<sup>3</sup>, D. Garrido<sup>3</sup>

<sup>1</sup>Laboratorio de Microbiología Clínica y Microbioma. Escuela de Medicina Veterinaria, Facultad De Ciencias De La Vida, Universidad Andrés Bello, Laboratorio, Chile, <sup>2</sup>Clínica Veterinaria Los Avellanos, Independencia, Santiago de Chile, Chile, <sup>3</sup>School of Engineering, Pontificia Universidad Católica de Chile., Department Of Chemical And Bioprocess Engineering,, TBA, Chile

**Introduction:** Obesity is a multifactorial nutritional disorder highly prevalent in dogs, both in developed and underdeveloped countries. It is estimated that over 40% of the canine population suffers from this disease, which manifests itself in an increased risk of suffering from chronic osteoarticular, metabolic and cardiovascular diseases. The intestinal microbiome in obese animals presents differences in the relative abundance of different phylos, changes that have been related to the ability to obtain energy from food via fermentation and increasing the bioavailability of carbohydrates present in the diet. In our country there are no investigations related to this topic.

**Objectives:** The objective of this study was to compare the intestinal microbiome of obese and normal weight adult dogs.

**Methods:** Twenty clinically healthy dogs were studied: 10 obese and 10 normal weight, classified according to their body condition. DNA was extracted from a stool sample, followed by massive sequencing of the 16S rRNA gene and bioinformatic analysis.

**Results:** The clinical study revealed statistically significant differences between the operational taxonomic units (O.T.U.) between both groups when analyzing major phylos: firmicutes and bacteroidetes

**Conclusions:** These results raise the need to continue research that relates the metabolic pathways used by these microorganisms and how they are associated with obesity.

**P072 / #521**

**Topic:** AS26 Pharmacology

## **PALATABILITY OF A NOVEL FORMULATION OF MILBEMYCIN OXIME/PRAZIQUANTEL TO INCREASE COMPLIANCE IN DOGS**

J. Kužner<sup>1</sup>, L. Prem<sup>1</sup>, I. Gobec<sup>1</sup>, D. Cvejić<sup>2</sup>, K. Hellmann<sup>2</sup>

<sup>1</sup>Krka, d. d., Novo mesto, Krka, D. D., Novo Mesto, Novo mesto, Slovenia, <sup>2</sup>Klifovet AG, Klifovet Ag, Munich, Germany

### **Introduction:**

Endoparasites are common in dogs and several of them are of zoonotic importance. Oral treatment with drugs known for bad taste (praziquantel) may be challenging and may result in poor compliance and treatment failures. Such products may be masked in food or they may be formulated with palatants to improve voluntary acceptance. Available data for similar combined products suggested voluntary acceptance of < 70%.

### **Objectives:**

To determine voluntary acceptance of novel (liver and meat aroma, yeast) Milbemycin oxime/Praziquantel 12.5 mg/125.0 mg tablets by Krka, d. d., Novo mesto (IVMP) in dogs.

### **Methods:**

This was a GCP-compliant and single-group, non-blinded, monocentric field study in client-owned dogs (various breeds and both sexes; n = 28). The acceptance test was repeated after 14 days (56 tests in total) as per the current EU guideline for palatability testing (EMA/CVMP/EWP/206024/2011). It assessed an overall voluntary acceptance, individual voluntary acceptance rate within 2 minutes (1 minute from the bowl/floor + 1 minute from the hand), and acceptance over time as well as failures. The palatability was considered sufficient if the overall acceptance met or exceeded 80%. Animals were observed for adverse events.

### **Results:**

The voluntary acceptance of the IVMP was 86%; acceptance was the same on both days (86%) and 4 dogs didn't accept the tablet (the same failure rates on both occasions). The product was well-tolerated, no adverse events occurred.

### **Conclusions:**

Selected flavours improved palatability of the novel product in dogs and is expected to be favourable for compliance in deworming of dogs.

P073 / #668

**Topic:** AS26 Pharmacology

## **QUALITY OF VETERINARY ORAL FORMULATIONS OF AMOXICILLIN/CLAVULANIC ACID IN WSAVA MEMBERSHIP COUNTRIES: STUDY DESIGN AND PRELIMINARY RESULTS FROM MALAYSIA AND THE UK**

L. Pelligand<sup>1</sup>, D. Baker<sup>2</sup>, A. Sivagurunathan<sup>3</sup>, P. Steagall<sup>4</sup>

<sup>1</sup>Veterinary Anaesthesia and Clinical Pharmacology, Department Of Clinical Services And Sciences, Department Of Comparative Biomedical Sciences, The Royal Veterinary College., Hatfield, United Kingdom, <sup>2</sup>Research & Innovation Fellow, Tba, TBA, United Kingdom, <sup>3</sup>Animal Medical Centre, Wisma Medivet, Lumpur, Malaysia, <sup>4</sup>Faculté de médecine vétérinaire, - Département De Sciences Cliniques, Quebec, Canada

**Introduction:** Substandard quality of antimicrobial formulations has negative consequences on patient care due to lack of clinical efficacy as well as potential implications for the selection of AMR due to under-dosing. Amoxicillin/clavulanic acid (AMC) is the most commonly used oral antimicrobial drug in companion animals worldwide. Both active ingredients are sensitive indicators for substandard quality, due to their limited stability.

**Objectives:** The objectives of the study were to detect types and frequency of deficits in the quality of veterinary oral formulations of AMC in various WSAVA member countries.

**Methods:** Prospective study with purposive sampling. AMC tablets formulations destined for canine use were collected from wholesalers, veterinary practice or markets from January to May 2021 and shipped to a central laboratory. Primary and secondary packaging inspection, uniformity of weight, disintegration and content assay tests were carried out, according to United States Pharmacopeia, using a validated HPLC method with UV detection.

**Results:** Fifteen sample formulations were collected (9 Malaysia and 6 UK); 6 were veterinary formulations. This yielded 13 different formulations, as two formulations were duplicate submitted from different locations. Secondary packaging was present for 11/15 samples. Primary packaging integrity was always verified. Median number of tablets per sample was 32 (range 30–100). Amoxicillin trihydrate / Potassium clavulanate ratio was 4:1 and 2:1 for 12 and 3 formulations, respectively. Content assay results are pending at this stage.

**Conclusions:** Results presented will encourage other WSAVA representatives to submit samples to this ongoing study, evaluating globally the prevalence of substandard and falsified formulations.

**Topic:** *AS28 Reproduction, pediatrics*

**UTERINE PATHOLOGY IN TWO CLINICAL CASES OF CANINE XX-SRY-NEGATIVE HERMAPHRODITISM AND FEMALE PHENOTYPE**

A.M. Garrido Leiva<sup>1</sup>, A. Vargas<sup>2</sup>, L. Monteagudo Ibañez<sup>3</sup>, J. Rodríguez Gómez<sup>2</sup>, B. Moreno Burgos<sup>2</sup>, O. Mitjana Nerín<sup>2</sup>, M. Falceto Recio<sup>2</sup>

<sup>1</sup>UNIVERSIDAD DE ZARAGOZA HOSPITAL VETERINARIO, Departamento De Patología Animal, Zaragoza, Spain, <sup>2</sup>Facultad de Veterinaria, Departamento De Patología Animal, Zaragoza, Spain, <sup>3</sup>Facultad de Veterinaria, Departamento De Anatomía, Embriología Y Genética Animal, Zaragoza, Spain

**Introduction:**

True hermaphroditism is one type of alterations in sexual differentiation that affects gonadal development: where ovarian and testicular tissue appear simultaneously, even in the same gonad (ovotestes).

In mammals, XY zygotes have the SRY gene on the Y chromosome, which determines the formation of the male reproductive system. In its absence, the differentiation of the ovaries and the female phenotype occurs.

**Objectives:**

To determine the sex and characteristics of the internal genital tract in 2 intact intersex females (hypertrophied clitoris and penile bone), who attended the check-up for sterilization.

**Methods:**

Two females are presented: 5 years-old, 25 kg bloodhound; and 1.5 years, 10 Kg French bulldog.

In both cases, abdominal ultrasound showed ambiguous gonads and uterine dilation. Chromosomal analysis and genetic study by PCR were performed. Hormonal levels in the blood, histological study of the gonads and microbiological analysis of the uterine content were carried out.

**Results:**

After chromosomal analysis, they were diagnosed as intersex ( $2n = 78$ ), XX-SRY negative individuals with a female phenotype.

Histological study confirmed the presence of bilateral ovotestes. In the first case, the uterine pathology was hydrometra and in the second pyometra. Hormones levels were compatible with those of a neutered male or a female in anestrus in the first bitch and with an intact male, in the second.

	BITCH 1	BITCH 2
Ultrasound / histology	Bilateral Ovotestes	Bilateral Ovotestes
Hormonal analysis	Testosterone: <5 ng/ml Estradiol: 11,9 pg/ml Progesterone 1,7 ng/ml	Testosterone: 103 ng/ml Estradiol: 9.87 pg/ml Progesterone < 0.2 ng/ml
Microscopic analysis	<b>Hydrometra:</b> absence of microscopic lesions and bacterial growth.	<b>Pyometra:</b> active chronic endometritis and positive culture for: <i>Staphylococcus pseudintermedius</i> and <i>Streptococcus canis</i>

Figure 1; Comparison of relevant findings found in clinical cases.

### Conclusions:

In disorders of sexual development, the study of the karyotype and the SRY gene is of great interest. Currently, in our XX-SRY negative patients we cannot explain the cause of sexual reversion.

**P075 / #469**

**Topic:** *AS29 Soft tissue surgery and Oncosurgery*

## **USE OF MINIMALLY INVASIVE THERMOABLATION IN THE TREATMENT OF CANINE ORAL MALIGNANT MELANOMA**

Y.W. Lin<sup>1</sup>, C.H. Yu<sup>1</sup>, C.C. Liao<sup>2</sup>, S.C. Huang<sup>2</sup>

<sup>1</sup>New Ruipeng Pet Healthcare Group Co., LTD, Shanghai Naught Family Veterinary Hospital, Shanghai, China, <sup>2</sup>Shanghai Youge Medical Technology Co., Ltd, Clinical Research, Shanghai, China

### **Introduction:**

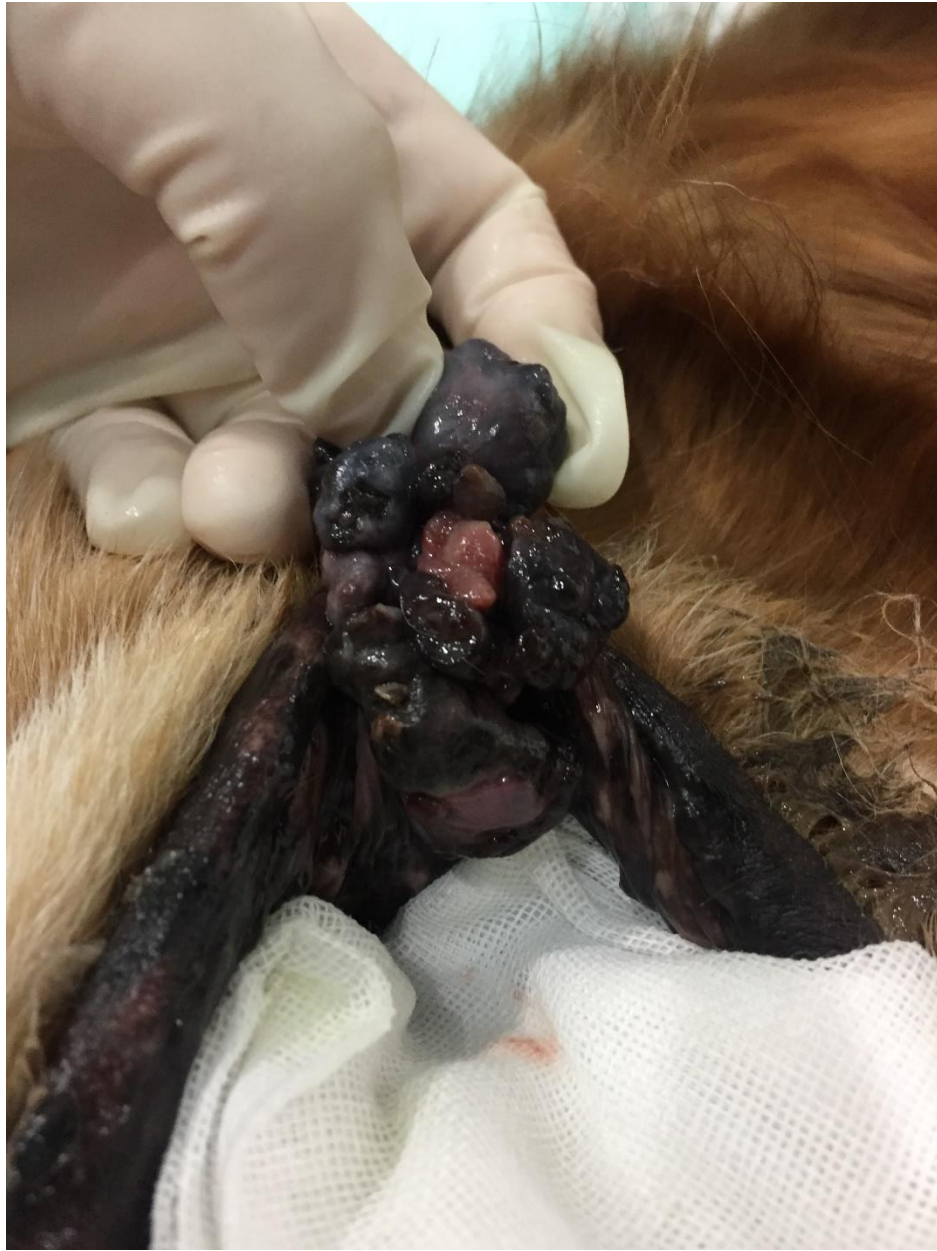Minimally invasive thermoablation (MIT) is a new method to treat cancer in the veterinary. The system includes a power generator and probes. The probes could be heated up to 100°C to ablate target tumor and cause necrosis. In this paper, a 10-year-old golden retriever, carried with an oral malignant melanoma would be treated by MIT.

### **Objectives:**

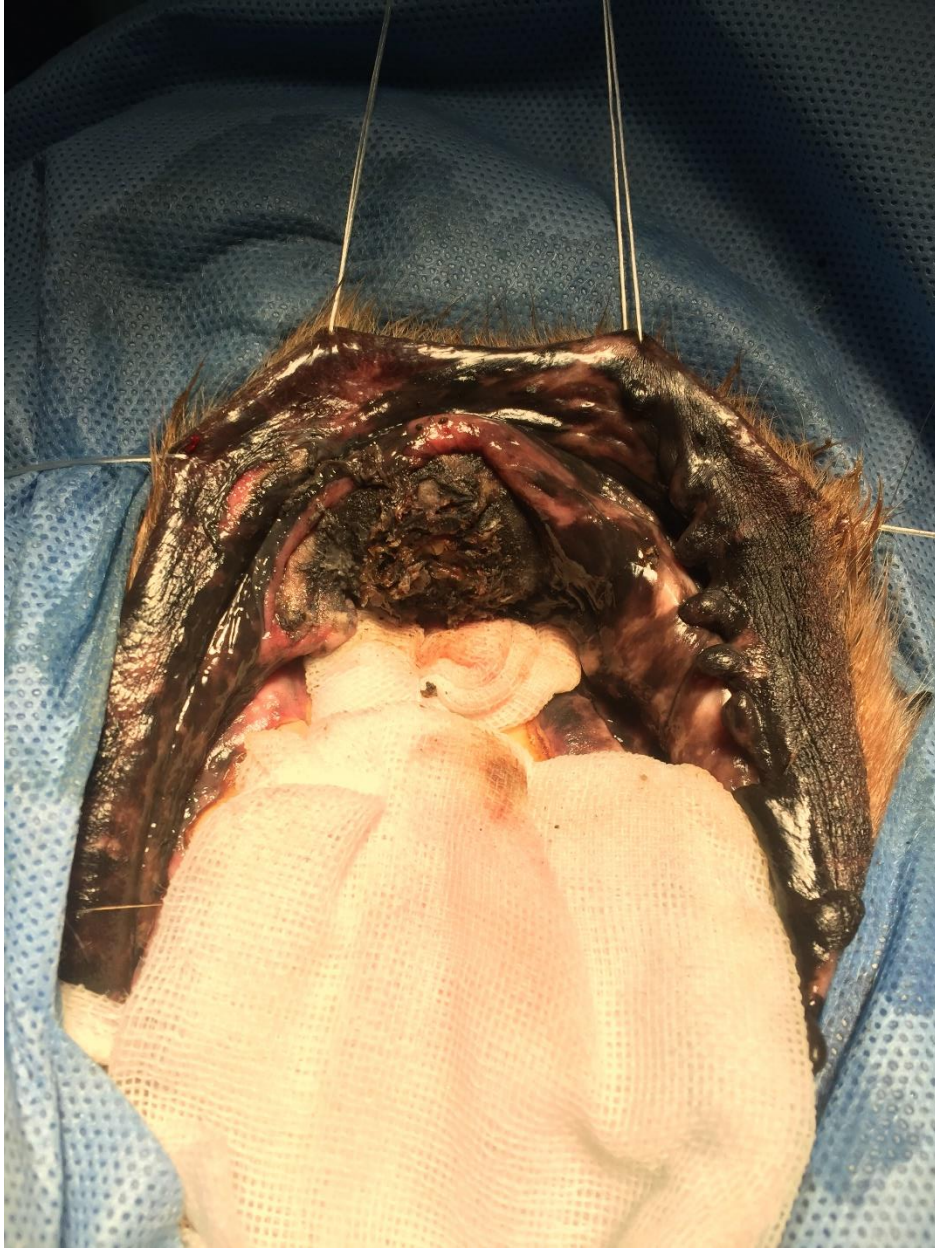
To observe the treating effect by MIT. We observed the tumor during the treatment and follow up for a week, a month and six months.

### **Methods:**

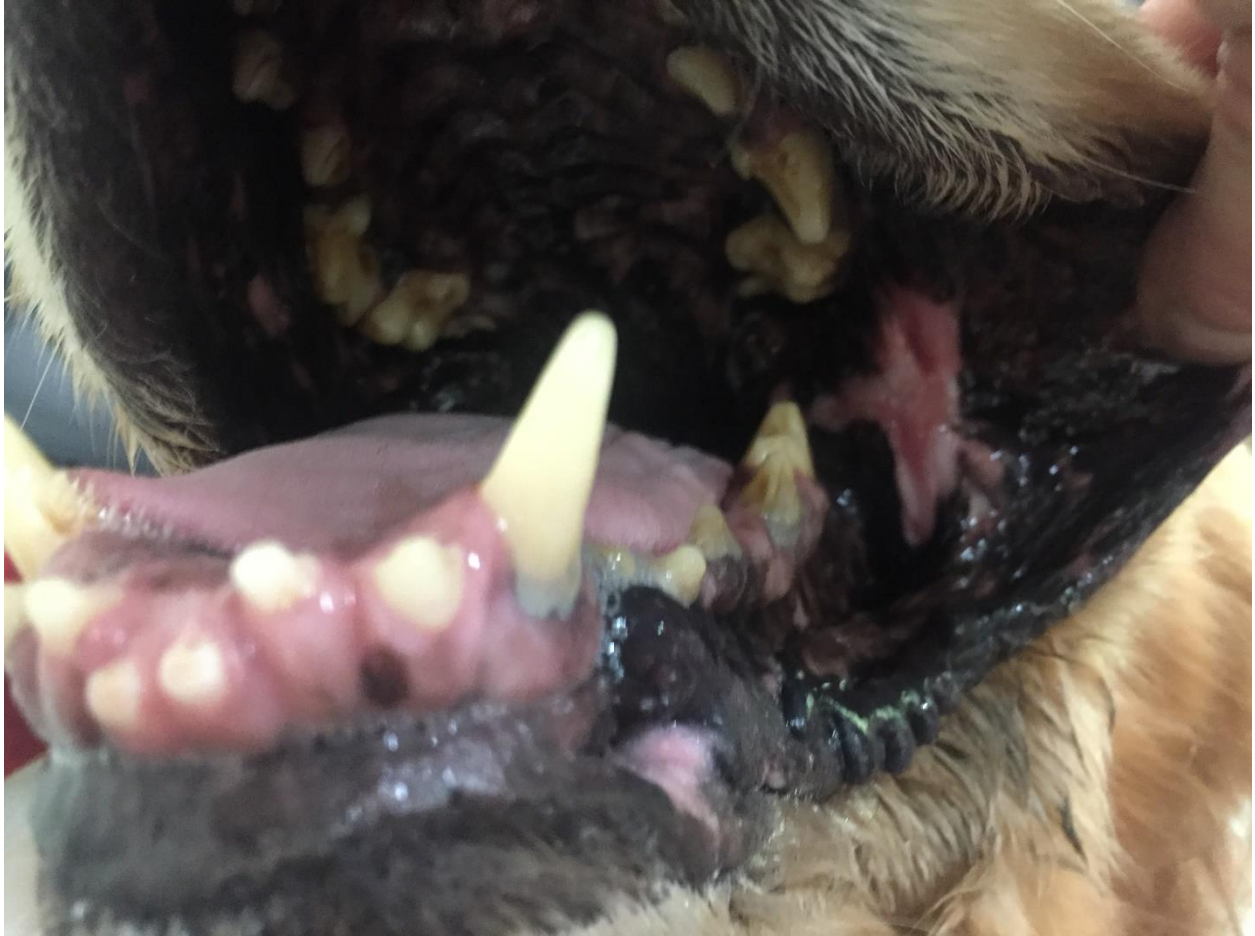The case is a 10-year-old golden retriever, carried with an oral malignant melanoma (fig.1). During the treatment, four probes were inserted into the tumor. Each probe was parallel and 1 cm between each other. After insertion, the probes were heated up to 100°C for 5 min. The tumor was necrosis after the heating, and removed by the surgery without any bleeding (fig.2).





**Results:**

The wound fully recovered a month after surgery (fig.3). There was no any side effect of MIT. We also followed up the case for six months, there was no any recurrence.

**Conclusions:**

The MIT is a new, effective and safe method to treat tumor in the oral. It is easy to use and shorten the surgery time to decrease the risk of the surgery. The MIT can also be used to treat solid tumor on the skin, face, and in the abdomen. It applied a powerful tool to treat the complicated cancer case.

**Topic:** *AS29 Soft tissue surgery and Oncosurgery*

## **TRICUSPID VALVULOPLASTY IN TWO DOGS WITH DEGENERATIVE VALVE DISEASE**

K. Mihara<sup>1</sup>, K. Sato<sup>1</sup>, Y. Suzuki<sup>1</sup>, I. Kanemoto<sup>1</sup>, K. Misumi<sup>2</sup>

<sup>1</sup>Chayagasaka Animal Hospital, Cardiovascular Surgery, Nagoya, Japan, <sup>2</sup>Kagoshima University, Joint Graduate School Of Veterinary Medicine, Kagoshima, Japan

### **Introduction:**

There have been no reports of successful tricuspid valvuloplasty (TVP) in dogs with degenerative valvular disease, nor of successful second open-heart surgery in dogs. Here, we present two cases of TVP in dogs with tricuspid regurgitation (TR)-associated right heart failure two or four years after undergoing mitral valvuloplasty.

### **Objectives:**

To describe surgical repair for two dogs with degenerative TR, and report the outcomes.

### **Methods:**

The dogs in this study were male Chihuahuas (Case 1: 12-year-old, 6.0 kg; Case 2: 11-year-old, 5.7 kg) that had undergone mitral valvuloplasty (MVP) to treat stage C myxomatous mitral valve disease four (Case 1) or two (Case 2) years previously. Following their initial surgery, both dogs had been monitored without receiving any further medication; however, their valve disease continued to progress, and they had heart failure due to degenerative TR, indicating that medical management had not been achieved. Both dogs underwent TVP on a beating heart under hypothermic cardiopulmonary bypass (CPB) without cross-clamping the aorta, because adhesion following the previous open-heart surgery had rendered the standard procedure problematic. The tricuspid valve was repaired using artificial chordal replacement (ACR) and tricuspid annuloplasty (TAP), similarly to reported MVP procedures.

### **Results:**

Postoperative echocardiography revealed a marked reduction in TR jet area and venous congestion. Both dogs have shown symptom-free survival through eleven (Case 1) or three (Case 2) months without receiving any further medication.

### **Conclusions:**

Satisfactory outcomes were achieved with TVP using ACR and TAP on a beating heart under CPB, as a successful, second surgical intervention for two dogs with degenerative valve disease.

**Topic:** *AS29 Soft tissue surgery and Oncosurgery*

**CASE REPORT: A NEPHRECTOMY IN A YOUNG FEMALE CAT WITH PERINEPHRIC PSEUDOCYST**

F. Amelia<sup>1</sup>, S. Zaenab<sup>2</sup>, O. Alamsari<sup>3</sup>, E. Zulfiati<sup>4</sup>, S. Siallagan<sup>5</sup>, B. Budiharjo<sup>6</sup>, B. Martin<sup>7</sup>, A. Zahrani<sup>8</sup>

<sup>1</sup>Mody Pet's Club & RnD Clinic by My Vets, Neurology And Rehabilitation, Jakarta Selatan, Indonesia, <sup>2</sup>My Vets BSD, Soft Tissue Surgery, Tangerang Selatan, Indonesia, <sup>3</sup>My Vets Kemang, Feline Medicine, Jakarta Selatan, Indonesia, <sup>4</sup>My Vets BSD, Anesthesia, Tangerang Selatan, Indonesia, <sup>5</sup>My Vets Kemang, Diagnostic Imaging, Jakarta Selatan, Indonesia, <sup>6</sup>My Vets BSD, Diagnostic Imaging, Tangerang Selatan, Indonesia, <sup>7</sup>My Vets Kemang, Soft Tissue Surgery, Jakarta Selatan, Indonesia, <sup>8</sup>My Vets Kemang, General Practice, Jakarta Selatan, Indonesia

**Introduction:**

A perinephric pseudocyst is defined as a fluid accumulation in the fibrous sac surrounding the kidney that may be located in a subcapsular or extracapsular region. The condition has been recorded mostly in male older cats.

**Objectives:**

This report aims to describe the unusual presentation of perinephric pseudocysts in a young female cat.

**Methods:**

A 2-year-old female exotic shorthair cat weighing 2.54 kg was referred for imaging evaluation of left-sided abdominal distention. The patient has a history of ovariohysterectomy (OH) due to pyometra four months before her visit. A radiological and hematological examination was then performed.

**Results:**

Radiographs showed deformity of the left kidney. Abdominal ultrasonography revealed a perinephric pseudocyst along with other abnormalities such as biliary sludge and mild splenomegaly. The hematological examination did not show significant changes, except for the leukocytosis. The nephrectomy through traditional laparotomy is performed to remove the affected kidney. Abscess fluid drained from the subcapsular region of the left kidney. A necrotic area is also observed in the abdominal muscles, making them thin and weak. The operation was successful, but the animal returned two weeks later for surgical repositioning due to a ruptured abdominal muscle.

**Conclusions:**

We concluded that perinephric pseudocyst should be considered as a differential diagnosis for cats with abdominal distension and abnormal shape/size of the kidney, regardless of their gender, age, and hematological findings. Imaging studies are crucial in establishing the diagnosis and evaluating the excretory function of the kidney. Nephrectomy via laparotomy can help to remove the affected kidney and has shown satisfactory results.

**Topic:** *AS30 Sports Medicine and Rehabilitation*

## **REHABILITATION IN COMBINATION WITH ACUPUNCTURE FOR TETRAPARALYSIS DOG CAUSE BY CANINE DISTEMPER VIRUS – A CASE REPORT**

O. Chingchit<sup>1</sup>, P. Chajunmethe<sup>2</sup>

<sup>1</sup>Thonglor Pet Hospital, Rehabilitation Center, Bangkok, Thailand, <sup>2</sup>Thonglor Pet Hospital, Internal Medical Center, Bangkok, Thailand

### **Introduction:**

A 3-month-old female Golden Retriever had CDV positive from ELISA test and PCR. The dog presented severe pneumonia, dermatitis, hypotension, leukocytosis. The dog responds with recombinant omega interferon sid 3 days, Metronidazole 10 mg/kg bid IV, Ceftazidime 20 mg/kg bid IV, Folic acid, antiemetic. After 1 month, the dog had partial seizure, myoclonus, tetraparesis, and bed sore, deep pain +1/4, sciatic +1/4.

### **Objectives:**

The case for presenting physical therapy and acupuncture help the infected paresis dog.

### **Methods:**

Starts physical therapy on 23 Jun 2019. She had tetraparalysis, bed sore on the left hip, left scapular and myoclonus. The first 2 months did physical therapy 5 days/week.

Laser was used to help stimulate wound healing, acupoints Liu-feng, Baihui, BL23, 14, 18, 40, 60, ST-36, LI4, 11 and GV20 for treat Jing deficiency with local wind. Massage and therapeutic exercise are delivered for stimulate blood circulation and building muscle. The walking exercise and underwater treadmill to improve muscle endurance.

### **Results:**

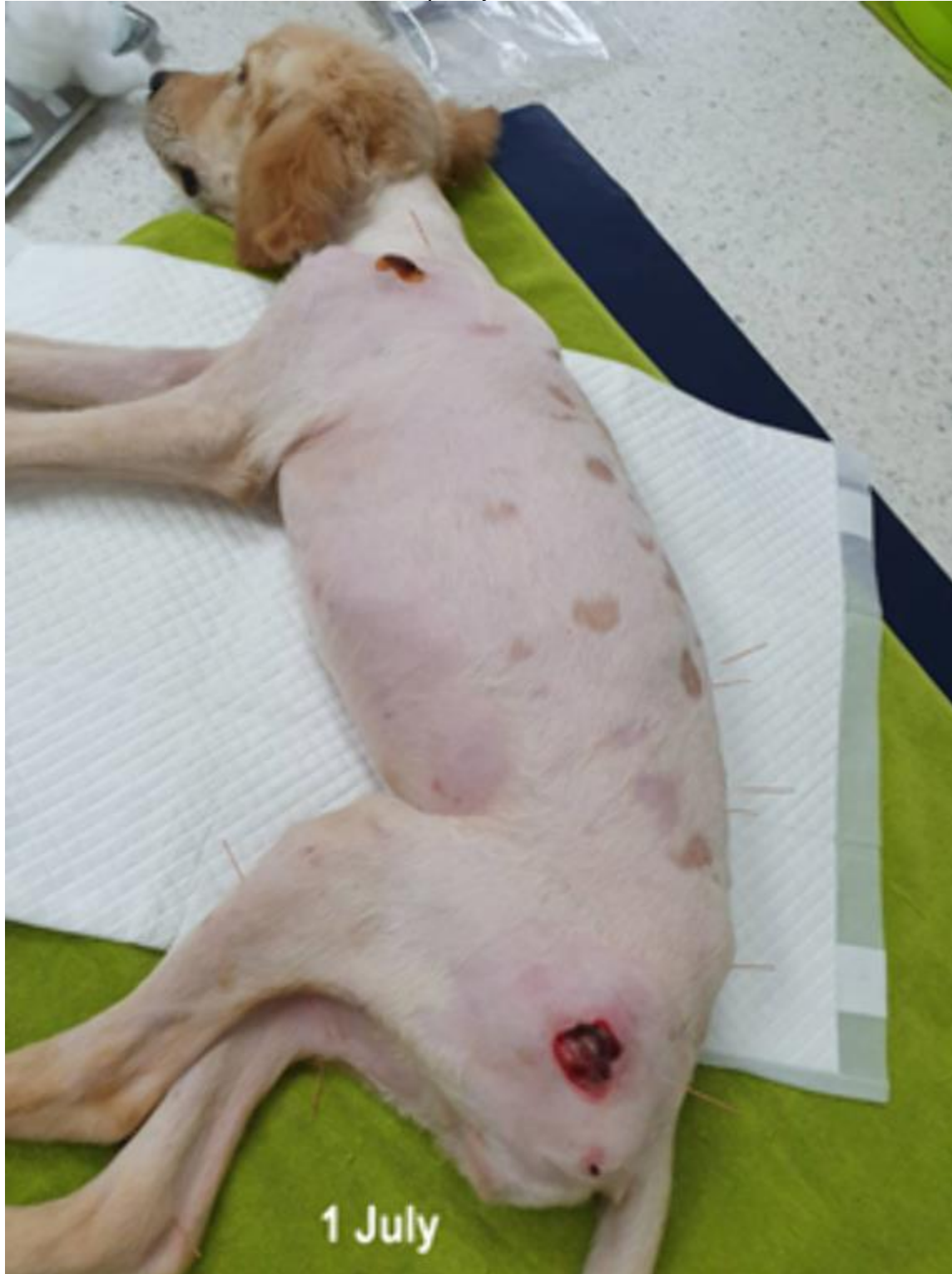The dog was able to walk, increase muscle mass, right hind leg weaker than left, no bed sore, myoclonus was reduced. Pain and lameness were decreased.

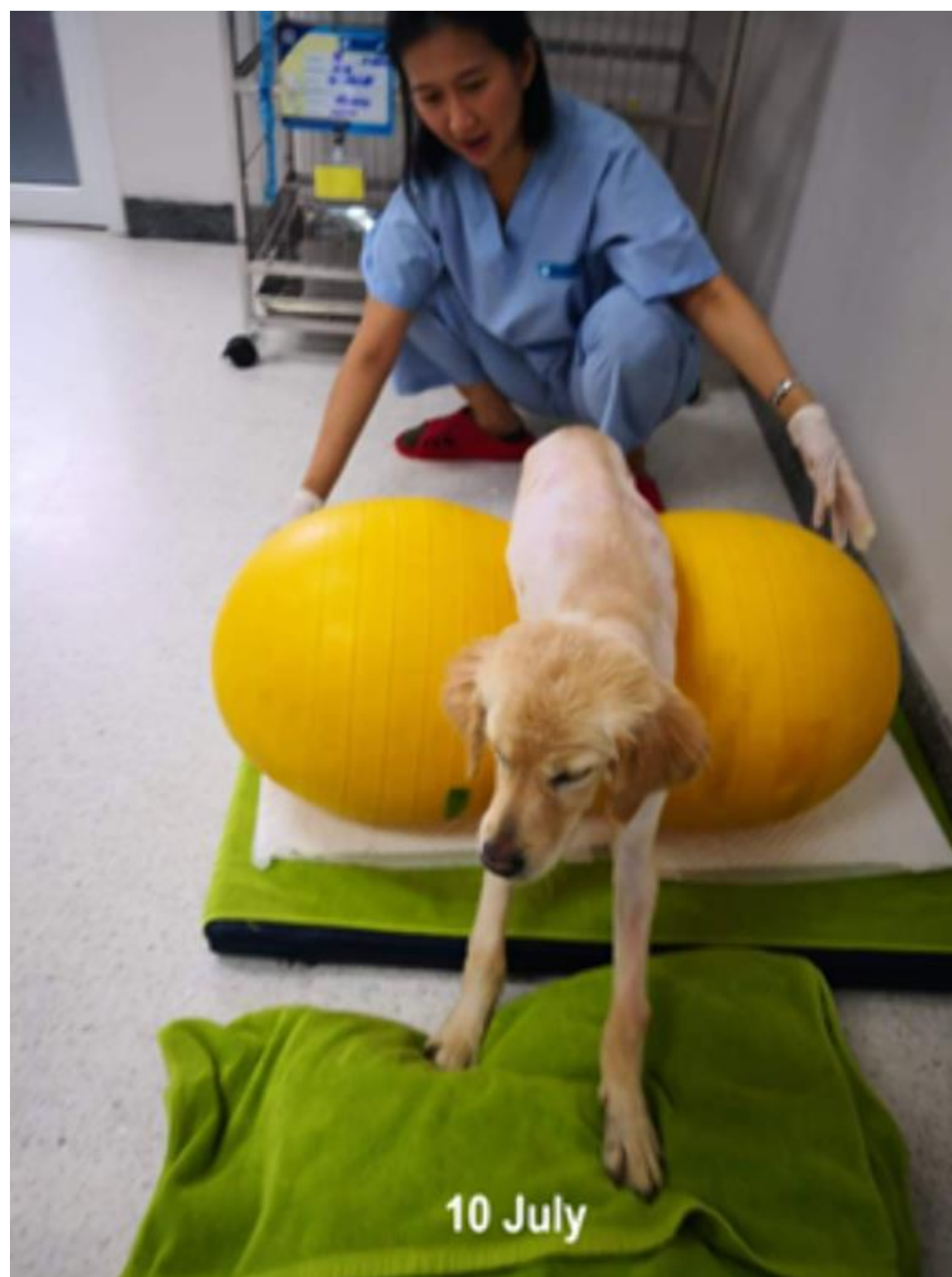Result in 12 weeks		
	June 23	September 22
Hind limb circumference		
Left	26.1	33
Right	23.8	32.1
Pain score	2/4	0/4
Lame score	Unable to walk	2/4




**Conclusions:**

Based on the case study, the intensive rehabilitation can improve clinical signs 2 weeks able assist walking, 4 week able to walk by herself, 8 weeks able to walk and run and 12 weeks muscle mass increased, walk and run quickly.









**P079 / #531**

**Topic:** *AS31 Teaching/Education*

## **USE OF A SIMULATED DOG FOR THE ASSESSMENT OF THE EFFECTIVENESS OF A CANINE BEHAVIOUR EDUCATIONAL INTERVENTION IN VETERINARY STUDENTS.**

J. Oxley<sup>1</sup>, G. Meyer<sup>2</sup>, I. Cant<sup>3</sup>, M. Butcher<sup>3</sup>, G. Bellantuono<sup>3</sup>, A. Levers<sup>3</sup>, C. Westgarth<sup>1</sup>

<sup>1</sup>University of Liverpool, Department Of Livestock And One Health, neston, United Kingdom, <sup>2</sup>University of Liverpool, Psychology, Liverpool, United Kingdom, <sup>3</sup>Virtual Engineering Centre, Virtual Engineering Centre, Daresbury, United Kingdom

### **Introduction:**

Aggressive behaviour in dogs is a welfare concern as well as an injury risk to veterinary staff. Therefore, veterinary students need to understand dog behavioural signals indicative of aggression.

### **Objectives:**

To determine if videos of a simulated dog model displaying aggressive and unresponsive behaviours can be used to assess the effectiveness of an educational intervention.

### **Methods:**

Forty first year veterinary students watched two videos per survey of a camera approaching an aggressive or unresponsive simulated dog and were asked to signal when they would stop. One group (n=17) received an educational intervention between two consecutive experimental runs, the other, control (n=23) did not. In each survey, participants were asked to rate their confidence regarding their ability to interpret canine behaviour. A Wilcoxon signed-rank and Mann-Whitney U test was conducted to test within and between group comparisons, respectively.

### **Results:**

The median time participants stopped approaching the dog was lower in the aggressive than in the unresponsive scenario over all videos ( $p < 0.001$  in all cases). However, there were no significant changes in response-stop time between the first and second survey for control and intervention groups for either dog scenario. A significant increase in confidence rating occurred for both the control ( $p = 0.003$ ) and intervention group ( $p = 0.001$ ), but there was no significant difference between groups.

### **Conclusions:**

Veterinary students responded differently towards the unresponsive and aggressive dog. Self-reported confidence in interpretation of dog behaviour did increase both for the control and experimental group. However, this did not translate to being more cautious when approaching the dog.

**Topic:** AS32 *Veterinary nursing*

## **BODY CONDITION SCORING IN CLINICAL PRACTICE IN NEW ZEALAND**

L. Harvey<sup>1</sup>, K. Cameron<sup>1</sup>, S. Fontaine<sup>2</sup>

<sup>1</sup>Unitec Institute of Technology, School Of Environmental And Animal Sciences, Auckland, New Zealand, <sup>2</sup>University of Glasgow, College Of Medical, Veterinary & Life Sciences, Glasgow, United Kingdom

### **Introduction:**

Body condition scoring is a simple, cost-effective way to assess the body condition of an animal. The WSAVA 1-9 scale is the most widely used and recommended of the validated tools available. Veterinary Nurses have a client-facing role in a veterinary practice and research suggests consistency in scoring in an experimental setting, however there is no data on the body condition score practices within clinical practice.

### **Objectives:**

This study examined the body condition scoring practices of veterinary clinics in New Zealand.

### **Methods:**

Respondents (veterinary nurses) answered questions about the body condition score system used in their workplace, the regularity of usage and recording of assessments, and their opinions on the value of body condition scoring.

### **Results:**

There were 77 respondents. Most veterinary clinics (72.7%) used the 9-point scale to measure body condition score, 48% scored during every visit, and 26% record the assessment. Almost a quarter (22%) of veterinary nurses do not know or do not agree that body condition scoring is a routine clinical parameter.

### **Conclusions:**

Although most clinics consistently use the same test, only half used the score over time and fewer recorded the visit, rendering the assessment of changes and trends over time inaccurate or impossible. Improving the regularity of usage of a body condition scoring assessment will improve the tracking of health in animals. Further education may be required to ensure VNs are aware of the importance of this as a routine clinical parameter in order to provide the impetus to facilitate change in practice.

**Topic:** AS32 *Veterinary nursing*

**EFFICACY OF DELTAMETHRIN-LOADED ZN-FE, ZN-AL-GA LAYERED DOUBLE HYDROXIDE, AND FE-O NANOPARTICLES AGAINST RESISTANT RHIPICEPHALUS ANNULATUS TICK**

S. Ibrahim<sup>1</sup>, S. Aboelhadid<sup>2</sup>, A. Wahba<sup>3</sup>, A. Farghali<sup>4</sup>

<sup>1</sup>animal health research institiuate, Parasitology, fayoum, Egypt, <sup>2</sup>Faculty of veterinary medicine, Parasitology, beni suef, Egypt, <sup>3</sup>animal health research institiuate, Parasitology, cairo, Egypt, <sup>4</sup>Faculty of Postgraduate Studies for Advanced Sciences, 4materials Science And Nanotechnology, beni suef, Egypt

**Introduction:**

Rhipicephalus annulatus (R. annulatus) tick is one of the most important ectoparasites affecting cattle production, also it is commonly controlled by deltamethrin. The over use of deltamethrin has resulted in the development of resistance.

**Objectives:**

To improve acaricidal effect of deltamethrin, therefore, deltamethrin was loaded on Zn-Fe LDH, Zn-Al-GA LDH, and Fe O-NPs.

**Methods:**

The Nano-composites (NCs) were prepared by the co-precipitation method and characterized before and after deltamethrin loading by X-ray diffraction (XRD), Fourier transform infrared (FT-IR), and Scanning Electron Microscope (SEM). The deltamethrin-loaded NCs were applied against the phenotypically resistant Rhipicephalus annulatus tick (adult and larvae) by adult immersion test and larval packet test at the recommended dose (X) (1 uL/mL distilled water ) and its bi-folds (2X, 3X, and 4X).

**Results:**

The adult ticks treated by deltamethrin alone or deltamethrin-loaded nanocomposites at different concentrations showed no mortality. Only a significant ( $P \leq 0.05$ ) reduction in egg production index was observed at the recommended dose (X) (1 uL/mL distilled water ) and its bi-folds (2X, 3X, and 4X) in ticks treated with deltamethrin/Zn-Fe LDH nanocomposites compared to deltamethrin alone. Moreover, no significant differences ( $P > 0.05$ ) were recorded in larval mortality between the treatments by deltamethrin alone and its loaded nanocomposites at the same concentrations.

**Conclusions:**

Zn-Fe LDH-, Zn-Al-GA LDH-, and Fe Oxide conjugated with deltamethrin slightly decreased the egg production index of the treated resistant adult R. annulatus tick. Therefore, the findings of

the present study showed that the acaricidal efficacy of deltamethrin was not improved against tick resistance after loading it with these nanocomposites.